

A Review on Total Hip Replacement

Dr.M.Sivasankar*¹,S.Arunkumar*²,V.Bakkiyaraj*³,A.Muruganandam,*⁴,S.Sathishkumar*⁵

1.Professor, 2.PG Scholar ,3.Assistant Professor, 4.PG Scholar, 5.PG Scholar

Department of Mechanical Engineering
SKP Engineering College, Tiruvannamalai, Tamil Nadu, India.

Abstract:

In this paper the authors review the literature of the total hip replacement (THR) after G.Bergman [13] in 1993-2015, this paper will help the researchers to predict the deformations of musculoskeletal structures and to explore the total hip replacement techniques.

Keywords: review, hip, THR, wear, fatigue.

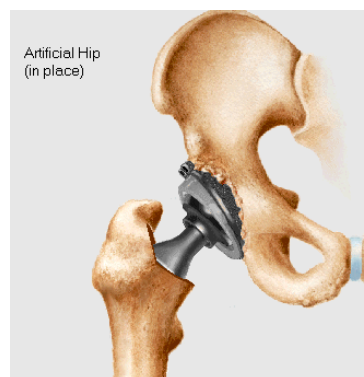
1. INTRODUCTION

Hip is one of the largest weight bearing joints in our body. It consists of two parts namely, a ball (femoral head) at the top of our thighbone (femur) and it fits into a rounded socket (acetabulum) in our pelvis. A band of tissues called ligaments connect the ball to the socket and provide stability to the joint. The hip joint may get damaged due to diseases like rheumatoid arthritis, osteoarthritis, fractures, and dislocations and sometimes due to accidents too. This may cause the fracture of hip and will give the permanent handicapping to the person. There are several types of hip fractures, like:

Femoral neck fracture: Pins (surgical screws) are used if the person is younger and more active, and if the broken bone is not removed much out of place. If the person is older and less active, a high strength metal device that fits into hip socket, replacing the head of the femur (hemiarthroplasty) is needed.

Intertrochanteric fracture: A metallic device (compression screw and side plate) holds the broken bone in place while it lets the head of the femur move normally in the hip socket. The Total Hip Replacement is the latest technology, which has been implemented as a boon for the humanity. By the implementation of the total hip replacement, the person who is facing the problem in the hip injury or meet with an accident will get benefited and it will enable the person to regain to normal work.

WHAT IS TOTAL HIP REPLACEMENT (THR) ?



A total hip replacement is a surgical procedure, which will alleviate the pain and debilitation caused by osteoarthritis, fractures, dislocations, congenital deformities, and other hip related problems. Where the diseased cartilage and bone of the hip joint is surgically replaced with artificial materials. The artificial hip may be made up of different materials like metals, Fiber etc., and the hip are in the shape of a ball and socket joint. The socket is a cup shaped bone of pelvis, which is called as acetabulum and the ball, is the head of the thighbone, which is also medically termed as femur. This process involves the surgical removal of the diseased ball and socket, and replacing them with a metal ball and stem inserted into femur bone and an artificial ceramic cup socket. The metallic artificial ball and stem setup is called as prosthesis. The replacement of the prosthesis can be done in three types namely **cemented**, **hybrid** and **cementless**. In the cemented prosthesis, the prosthesis will be inserted inside the core of the femur and will be fixed using the cement called **methylmethacrylate**. In hybrid prosthesis, the part in the pelvis bone is not cemented while the other part is fastened to the thighbone with cement. The prosthesis component in the pelvis bone is called Ringloc, and it is pressed into position. With time, it takes root as the bone attaches to the uneven surface of the prosthesis. In cement less prosthesis, there will be microscopic pores, which will allow the bony in growth from the normal femur into the prosthesis stem. The second type is used generally in operations for the younger patients to get the growth early. Generally both cementless (also called uncemented and porous-coated) and cemented hip replacements gives patients effective long-term relief. In late 70s the cement was used in total hip replacements to attach implants to the femur and acetabulum. At that time loosening of the implants was the greatest shortcoming of hip replacements. When revision operations were done to correct the problem, the success rate was lower than with the initial surgery.

This paper gives the review on various concepts like estimation of force on hip joint and fatigue of composite materials. This paper also discusses various materials used for hip prosthesis along with various design considerations. Various standards available for fatigue testing of stems and their methods along with the fatigue performance of the composite hip prostheses are presented. Finally objectives of present work are defined.

2. ESTIMATION OF FORCE ON THE HIP JOINT

Detailed knowledge about the *in vivo* loading of hip prosthesis is needed for accurate stress analysis, design, optimizing their design and materials, and mechanical testing of implants for strength, friction, wear and fixation stability. The resultant hip joint forces were measured during different activities like walking, running, jogging and stumbling using telemetering by several researchers. Bergmann *et al.* [12-16] measured the hip loading in two patients using instrumented hip implants during walking and running. The joint loading was observed following the implantation. In case of first patient (with two implanted hips) the peak forces were increased from 280% of the patient body weight (BW) at 1 Kmph to 480% BW, jogging raised the forces to about 550% BW and stumbling causes up to 720% BW. Where as in case of second patient (with only one implant) resulting forces are 440% BW at 3Kmph and a force of 870% BW was observed during stumbling. The torsional moments around the stem of the implant were 40.3 Nm in first patient and 24 Nm in second patient. The stresses in implant and bone are influenced not only by the magnitude and direction of the joint force that acts at the head of the implant but also by different activities.

Bergmann *et al.* performed measurement of hip contact forces with instrumented hip implants in four patients with detailed documentation of corresponding force values. From the individual data sets an average was calculated. The maximum force was observed in different patients during different activities, but in all patients either of climbing upstairs or going downstairs causes the maximum loading. When going upstairs the average torque is 23% higher than during normal walking. The maximum hip force observed during slow walking at 4 Kmph is 255% BW, during fast walking it is 279% BW. While going upstairs is and going down stairs is 316% BW. All the data obtained during this test is less than that obtained by Bergmann *et al.*

L. VOGT [150] examined the hip abductor activation pattern of 14 hip replacement patients and 10 age-matched healthy controls by measuring surface electromyography (EMG) onset and cessation times. Stride characteristics, surface EMG from bilateral gluteus medius, and 3D pelvis kinematics they evaluated during treadmill ambulation. EMG onset times they normalized with regard to the individual stride time for each gait cycle. An ANOVA revealed significantly delayed EMG onset times ($p < .001$) in comparing hip abductors of the operated side with the unimpaired side and the healthy controls. Between subject effects also demonstrated significant differences ($p < .01$) for stance duration and sagittal pelvis range of motion. No significant differences they found for EMG cessation times and angular pelvis peak-to-peak ranges in the frontal and transverse planes. The results indicated deficiencies in the hip abductor recruitment pattern of hip arthroplasty patients. Further analysis should explore whether specific exercises, or rehabilitation programs can facilitate adequate muscle activation.

Damien P. Byrne [34] revealed that the hip joint is unique anatomically, physiologically, and developmentally; therefore understanding the basic structure and biomechanics of the hip is essential for clinicians, physiotherapists and engineers alike. In this review they outline the function of the key anatomical components of the hip and discuss the relevant related biomechanical issues. Understanding the forces that cross the hip and the details of the anatomy leads to a better understanding of some of the failures of the past and gives credence to current and future solutions. They have provided a concise review of the anatomical and biomechanical basics of the hip for the patient, clinician, physiotherapist and engineer. The approach to learning and understanding hip anatomy can be undertaken in a number of ways as can the biomechanics. Understanding of the forces that cross the hip and of the details of the anatomy leads to a better understanding of some of the failures of the past and gives credence to current and future solutions.

3. DESIGN AND MATERIAL SELECTION

Literature review on FE analysis includes the various design considerations and the application of design optimization. There are various design considerations, which eventually affect the stability and the long-term applications are discussed in this context. The interfacial stresses are the main reason for the implant micro motions and finally leads to implant loosening. This will be avoided by reducing the interfacial stresses.

Scifert *et al.* [10],[126] has developed a new design concept that has been developed to reduce the propensity for dislocation. The new design involves convex curved acetabular lip, extending from the hemispherical articulating surface to the outer edge of the cup. Hip dislocation is the second leading reason for hip failure and observed by 2-11% of the patients, and 5-25% with revision surgeries. For studying the dislocation phenomenon, a 3D non-linear FE model was developed. The new design achieves 28% more resisting moment build-up during dislocation. The new curved lip design also develops 50% less polyethylene Von-Mises stress in the impinging zone. Excessive rim damage on the acetabular liner was observed in patients with hip dislocations. Fully non-linear frictional sliding contact analyses were conducted using ABAQUS® software.

Phillips [111] investigated the behavior of the acetabulum and impacted morcelised bone graft following revision hip arthroplasties and a 2D FE model of the acetabulum was developed. Plane strain elements were used to better representation of 3D situation. The inside diameter of the acetabular cup is taken as 50mm and of consisting four layers plastic, cement, graft and bone. The plastic, cement and bone are considered as linear elastic materials and graft layer was considered as elasto-plastic material. The maximum force applied to the model was 1000% BW, which is more than that measured by Bergmann *et al.* [1-3] and body weight is assumed as 1000N.

Kowalczyk [80] investigated the optimization of cementless femoral hip. Implant separation from bone tissue is a serious drawback and the reason for it is the unnatural stress distribution around the implant. Stresses and motions in bone and implant depend mainly on loading conditions and implant design. Optimization of implant properties, especially its geometric parameters have been done to improve the reliability of joint prosthesis. Initial stability criterion was taken as the optimization goal [12, 32, 33]. Precise mechanism of aseptic loosening is not clear; however mechanical rather than medical factors play an important role. Load transfer between a stiff implant and relatively flexible bone results in extremely unnatural stress distribution, i.e., excessive stress concentrations near to the implant ends, and stress shielding followed by resorption in areas of bone-implant interface. Titanium implant with young's modulus 110 GPa and cortical bone is having young's modulus 17 GPa were taken as the material properties for analysis.

Chang *et al.* [23], [97] conducted experiments on the design of robust total joint replacements under the influence of environmental variables. The optimum design for one environment is also robust to the alternate distributions and a sensitivity analysis technique has shown to determine influential design and environmental factors. Hip joint force orientation was more influential than the controllable design variables on bone remodeling and the cancellous bone elastic modulus has more influence on relative motion. A three dimensional nonlinear finite element model was used to predict the structural response. The design concept was characterized by two design variables; a reduced midstem diameter and a bullet tip length. Here total length of implant stem is fixed. The environmental variables considered are joint force angle, cancellous bone elastic modulus and implant-bone interface friction. Finite element model was developed using PATRAN software and contained 20-noded brick elements. The implant was modeled as linearly elastic and isotropic of cobalt chrome. Bone properties were also assumed to linearly elastic and isotropic but with an inhomogeneous distribution. The hip contact force and abductor muscle force were applied as point loads to the femoral head center and greater trochanter.

Senapati and Pal [129] had done FE analysis on a simplified three-dimensional (Axi-symmetric) model. Generally used metal and metal alloys cause severe stress shielding at the proximal part of the femur and the interface stress is concentrated at the distal tip of the prosthesis giving rise to mid thigh pain. All the bone, cement and the prosthesis materials are assumed to be linear, elastic, isotropic and homogenous materials. The peak value of stresses at the bone cement interface occurs at the proximal or distal end of the prosthesis and the peak interface stress at the prosthesis tip decreases with decreasing prosthesis stiffness. The influence of prosthesis materials like CoCrMo alloy, Ti6Al4V alloy and UHMWPE (Ultra-High-Molecular-Weight-Polyethylene)-Al₂O₃ ceramic composite on the stem interface stress were evaluated. The boundary conditions at the distal end had no effect on the stresses in the proximal region. The load applied on the femoral head is three times the patient weight and patient weight was taken as 600N. For a stiffer prosthesis material (CoCrMo alloy), the peak interface stress occurs on the distal end of the stem where as for a flexible implant like UHMWPE-Al₂O₃ the peak interface stress occurs at the proximal end i.e. a more flexible stem or less stiff materials cause more proximal load transfer. The pain in the patient was lower when the ratio of flexural rigidities of prosthesis and bone is lower.

Selvaduray [128] [107] [58] [44] discussed the factors to be considered in the material selection for hip implants. The first and foremost criterion is biocompatibility. It is the measure of the interaction between the foreign material and the bone tissues of the human body. The second criterion for material selection is the similarity of mechanical properties between bone and the material. Another property during material selection is corrosion resistance. Ti-6Al-4V provides better corrosion resistance than the cobalt-chrome alloy. Biological or cementless fixation is preferred for young patients whose bones are still growing and the living bone tissue is allowed to grow into the pores of a metallic implant. Biological fixation is capable of forming a much stronger bond than the cemented fixation due to the bone ingrowth at several points. The bone-implant interfacial stresses are reduced due to the large area of contact obtained by tissue ingrowth. Collar is provided where the neck meets the stem. This collar is used to disperse the load applied to the stem.

Katozian *et al.* [33],[117],[120],[43] developed a numerical optimization technique to design a fibre-reinforced composite to minimize the potential for bone remodeling and stress shielding. In this study material design variables are incorporated into the optimization of the femoral component of the hip prosthesis. In this investigation two different design objectives (failure-based and stress shielding-based) have been used to design a carbon fibre-reinforced composite implant. There are several advancements in design and manufacturing of hip prosthesis, but the complications still exist because of interface loosening and bone resorption. Cancellous bone resorption is due to the mechanical mismatch between the bone and the implant material. Almost all the current monoclinic implants are having a stiffness of 5 to 20 times of the bone. After the Total Hip Replacement (THR) most of the load is carried by the implant, due to its greater stiffness. Due to this reason unnatural stress distribution will exist at the interface of the bone and implant. Flexible stems result in more uniform load transfer, thereby reducing both stress shielding and bone resorption. Recent advancements in design and manufacturing technology of fibre-reinforced composite materials offer more strength comparable to that of metals and also more flexibility than metals.

A carbon fibre-reinforced polyether-etherketone (CF/PEEK) composite was considered for the implant material. CF/PEEK can give strength ranging from 70 GPa to 1900 GPa and stiffness ranging from 10 GPa to 100 GPa. The design variables considered are the volume fraction of fibres ($V_f=0.3$) and two orientation angles. The lower and upper bound constraints on the fibre volume fraction were assumed to be 10% and 70% respectively. Beyond this range of V_f material properties are highly dominated by matrix or fibres. Initial design fibres were oriented in the longitudinal direction of the femur and fibre-matrix constructs transversely isotropic, the stiffest direction of the implant was along the stem axis. In the failure based objective function, by changing the orientation of fibres, large reductions of Von-Mises stress in all regions occurred. The interfacial stresses between bone and the implant were smoothed. After optimization the average reduction in peak interface stress was about 67%. By changing the orientation of fibres match between interfacial stresses in pre and post-operation could be greatly improved. This will reduce the risk of stress shielding and subsequent bone resorption.

Weisse *et al.* [153] did an optimization of a proof test procedure of ceramic hip joint ball heads. The proof test rejects defective samples in the production line before implanted into human body. Thereby on every ceramic ball head a static load is applied, which was somewhat higher than the maximum physiological load. The magnitude of the applied load should not damage the samples, which were free of flaws in the high stress area. The configuration of proof test influences the stress distribution in the ball head, which should be similar to the physiological case. To determine the stress distribution, a non-linear finite element analysis was performed and the results were validated by measurements.

Brent M. Ardaugh [20] discovered the Medical Device Amendments of 1976 created three classes of devices: class I included low-risk devices, such as toothbrushes; class II contained moderate-risk devices, such as infusion pumps; and class III included high-risk devices and those awaiting proper classification, such as metal-on-metal hip implants. These classes roughly corresponded to the level of premarketing review required. Thus, class I and II devices underthey nt review for substantial equivalence to devices already on the market, also called preamendment devices (although subsequent legislation granted exemptions). Class III devices theyre meant to undergo the more rigorous premarket approval (PMA), the only pathway that requires clinical data. Hotheyver, class III devices they are allotheyd to receive review for substantial equivalence temporarily, until the FDA down-classified these devices or promulgated regulations requiring PMA.

4. EXPERIMENTAL, FINITE ELEMENT AND FATIGUE ANALYSIS

Waideet *al.* [152] analyzed the modeling of the fibrous layer in cemented hip replacements with experimental and finite element methods. The study he used was for both experimental and finite element method also to investigate the load transfer characteristics of two types of cemented hip replacements (Lubinus SPII and Muller-curved) with a fibrous tissue layer. In the experiment, he investigated six stems of each type, where these were implanted in composite femurs with a specially selected silicone elastomer modeling the soft interfacial layer. Two fibrous tissue conditions he has taken for the examination. (i) A layer covering the full cement mantle, representing a revision condition and (ii) a layer covering the

proximal portion of the cement mantle, representing a non-revised implant with partial debonding and fibrous tissue formation. The finite element method was used to model the full fibrous tissue layer condition, for both implants. The layer was modeled as a homogeneous, linearly isotropic material. A cross-comparison was performed of the experimental and finite element findings. The agreement between experimental and finite element models was verified to be within 15%.

Scotchford *et al.*, [127] analyzed the use of a novel carbon fibre composite material for the femoral stem component of a THR system. For this total hip replacement (THR) he had developed a novel, low elastic modulus femoral component using a composite of polyetherketone and carbon fibre. He has investigated human osteoblast-like cell and macrophage responses to this material in vitro. The cells were grown on composite discs and controls. The in vitro biocompatibility assessment of the composite they have taken showed the initial osteoblast attachment at least comparable to that of the tissue culture plastic and Ti6Al4V controls, with proliferation similar to the controls at all time points up to 11 days. Alkaline phosphatase activity was similar to that of Ti6Al4V but reduced compared to tissue culture plastic controls. Whilst hydrogen peroxide production by macrophages was raised on composite surfaces compared to controls, β -glucuronidase activity and osteoblastic production of Type I collagen and osteocalcin were similar to levels detected on Ti6Al4V.

Santiset *et al.*, [123] and his group analyzed the characteristics of composite with the help of micro mechanics and laminate theory for the implementation of them to the repairing of connective tissues in the surgical care of orthopaedic and dentistry patients. They analyzed the mechanical behaviour of polymers and continuous fibre reinforced polymers and compared to the behaviour of connective tissues. The design and the manufacturing of composite structures, which are made-up to simulate the mechanical properties of the soft and hard tissues surrounding the prostheses, are also reviewed. The authors have introduced a novel functionally graded composite mandible to be used for in vitro investigations. They have used Hydro Thane (Hydrophilic Thermoplastic Polyurethane by Cardio Tech International) is a family of hydrophilic thermoplastic polyurethane elastomers with adequate mechanical properties.

The biomechanics of bone growth, absorption, fracture healing are related to material properties, structural properties and bonding characteristics of the implant. The design of homogenous and isotropic devices can at most capture the geometry of the natural tissue, while the material-structure designs of composites provide a wider set of options and possibilities in implant design. The authors concluded that the design of materials for composite orthopaedic prostheses mainly focuses on carbon, glass or polymeric fibres reinforced polymers, which are lightweight materials with adequate strength and stiffness. The glass fiber reinforced plastics are mostly used in the design of polymeric composite materials. The mechanical properties of the fiber-reinforced composites are more similar to the properties of the natural bones. The filament winding technique is especially preferred when the component suggests an axial symmetry.

Mavcic *et al.*, [92] analyzed the forces acting on the hip and the peak stress in the hip joint and other relevant radiographic and biomechanical parameters using a mathematical model of an adult human hip in the static one-legged stance position of the body. The aims of the mathematical model assessing were to

examine if the peak stress in dysplastic hips is higher than in normal hips. Also he measured as, the normalized average peak stress in dysplastic hips (7.1kpa/N) was markedly higher than the average normalized peak stress in normal hips (3.5kpa/N) there were deviations in the size, shape, mutual proportions or orientation of acetabulum and femoral head are described as hip dysplasia. The hip joint stress is an important parameter in assessment of hip dysplasia, the results of B.Mavcic et al., [28] were consistent with the hypothesis that dysplastic hips have considerably elevated cumulative contact stress extra and the recent studies of them had reported that the relative maximum hip joint contact stress was higher in healthy women than the men. As the woman have higher incidence of arthrosis, the scientists came to a conclusion that the increased contact stress in the hip joint can be one of the reasons for the development of arthrosis.

Teoh *et al.*, [142] took a finite element model, based on ultra high molecular weight polyethylene (UHMWPE) to study the wear behavior of UHMWPE acetabular cup, which has a 33 mm diameter femoral head. He has developed a new computational model based on an elasto-plastic finite element model for the assessment of wear and a new mesh design. The wear simulation combined the influences of contact stress, sliding distance and a surface wear coefficient. The model was used to study the effect of friction and the clearance between UHMWPE cup and the femoral head. The UHMWPE head was taken as 8mm thick having a modulus of 1.4Gpa and a poisson's ratio 0.3 denoting the stiffening arising from in sit oxidation. In this he has used the 8noded brick element for his finite element formulation The volumetric wear rate was much higher with them compared with the previous published work and closer to clinical data.

Zimmerman *et al.* [157] observed and compared the outcomes of 271 cases of hip osteoarthritis receiving primary total hip replacement from numerous surgeons in 12 Baltimore region hospitals from 1991 to 1993. Their results indicated that that, while the totally non-cemented prosthesis was more costly, there were no statistically significant differences in clinical or functional outcomes between the non-cemented and the hybrid prostheses upto 12 months post surgery.

Stansfield *et al.* [137] ,[138] studied about two subjects with instrumented hip joint prostheses. Forces at hip joints were calculated using a three-dimensional model of the leg in walking at slow, normal and fast speeds (0.97 to 2.01m/s), and weight transfer from two to one leg and back again and sit to stand positions also were studied. Direct comparisons were made between the "gold standard" measured hip joint contact forces and the calculated forces.

Hurwitz *et al.* [62] developed an analytical model to estimate the natural biological variations in muscle forces and their effect on the hip forces subject only to physiological constraints and not predefined optimization criterion. The main objectives of the persons are to describe the parametric model and to assess the effect of antagonistic muscle activity on the peak forces in a subject with a THR and to compare the modeled forces to in vivo data collected by others. The force predictions were based on the joint kinematics and kinetics of each subject with a previously published muscle model, and physiological constraints on the muscle force distributions. They determined the hip contact forces also throughout the stance phase of gait of a subject with a total hip replacement.

Saiko and Calonius [121] did a slide track analysis of the relative motion between femoral head and acetabular cup in walking and in hip simulators. They have developed a new computation method based on Euler angles and used to compute slide tracks for the three axes motion of the hip joint in walking and for two hip simulators, the HUT-3 and the biaxial rocking motion.

Chang *et al.* [24] did the design and analysis of robust total joint replacements. They did the finite element model experiments with environmental variables, the optimal search of them indicated that only 16 to 22 computer simulations were necessary to predict the optimal design, a significant savings over traditional search techniques.

Kirkwood *et al.*[78] did an analysis on radiographic and non-invasive determination of the hip joint center location with effect on hip joint angles, also they made a measure on which of the four non-invasive measures was most accurate in locating the hip joint center. They found the hip center location using standard x-rays and four non-invasive methods, which utilized measured distances between bony landmarks in 10 healthy subjects. The hip moments during gait were obtained from optical tracking, force plate and anthropometric data. They found that the most accurate non-invasive method for locating the hip center was by taking the midpoint of a line connecting the antero-superior iliac spine and the symphysis pubis and moving inferiorly 2cm. Using this approach the hip center was located 0.7cm medial and 0.8cm superior to its true location determined using the standard x-rays.

Miller *et al.* [95] took an orthotropic material model to predict the proximal femur trabecular structure. They took two hypotheses to determine the local orientation and material properties of each element in the model. First was suggested that the maximal principal stress directions due to the multiple load cases the femur is subjected to determined trabecular directions, which correspond to the orthotropic material axes, locally. The second hypotheses they took were the material properties in each material direction could be determined using directional stimuli. They utilized an algorithm where each iteration comprised of two stages. First, material axes were rotated to the direction of the largest principal stress that occurred from a multiple load scheme applied to the proximal femur. Then the material properties were modified in each material direction. They concluded that the local material directions correspond with known trabecular patterns, reproducing all main groups of trabeculae very well.

Hertzler *et al.* [59] did a study over the femoral components using combination of experimental and computational methods to find the fatigue crack propagation process from stem-PMMA cement interface using a novel torsional loading model which was constructed using thin (1 mm), medium (3mm) r thick (7mm) cement mantles. They found that the crack growth was stable for all the cases and the rate of crack growth diminished with increasing crack length. When they combined the experimental findings with a fatigue crack growth Paris-law for PMMA cement, they found that the finite element models provided reasonable predictions of the crack growth process. The results they got were illustrating that the crack propagation from the stem-cement interface was a stable process under the conditions applied in the study. By this they came to a conclusion that the crack growth rate would be higher for constructs with thin cement mantles when compared with thicker cement mantles.

Sibella *et al.* [131] developed a biomechanical model using inverse dynamics equations for describing the sit-to-stand (STS) movement using kinetic and kinematic experimental data. The aim of their study was to develop a biomechanical model for a quantitative description of STS motion strategy in normal and obese patients. They found in the patients of obese that the kinetics of movement showed the knee joint torque higher than hip torque (maximum knee torque: 0.75 Nm/kg and maximum hip torque: 0.59Nm/kg) while normal patients showed the opposite behaviour (maximum knee torque: 0.38Nm/kg; maximum hip torque: 0.98 Nm/kg). They had suggested a biomechanical model for the comprehension of STS movement in normal and obese people. In particular a model of the belly was introduced to underline the role of the fat mass in the impairment of the obese people during STS movement. They had chosen the STS movement because it is a commonest movement and highly repeatability in normal persons.

Hallabet *et al.* [56] did an analysis on differences in the fretting corrosion of metal-metal and ceramic-metal modular junctions of total hip replacements. They did an investigative study on metal-metal modular connection and metal-ceramic modular connections. They used an in vitro comparison of ceramic (zirconia, ZrO₂) and metal (Co-alloy) femoral head fretting upon Co-alloy stem components. In this study of a single total hip replacement stem and head design, zirconia heads mated with Co-alloy stems produced less fretting than Co-alloy heads mated with Co-alloy stems.

Varanasi and Rajadurai [146], made an analysis on a prosthetic hip joint using fracture and stress analysis. They did both the modeling and analysis of the prosthetic hip and they analyzed the reasons for the fracture and distribution of stresses developed at various regions in the prosthetic hip under normal working conditions of the person to which the data had been acquired. They made the model using cast iron and modeled using ANSYS 5.4. They found the stress distributions at different loads in the prostheses hip joint.

Siegele *et al.* [132] did stress analyses over the ceramic hip joint heads under different loading conditions and by that they found the elastic deformation with corresponding stresses in the head by both experimental and numerical analyses as a basis of integrity tests of ceramic heads.

Lennon *et al.* [83] developed an experimental model of the implanted proximal femur that allowed visualisation of damage growth in the cement layer. Five matt surface and five polished surface stems were tested. Pre-load damage and damage after two million cycles was measured. Levels of pre-load (shrinkage) damage were the same for both matt and polished stems; furthermore damage for matt vs. polished stems was not significantly different after two million cycles. This was due to the large variability in damage accumulation rates. Finite element analysis showed that the stress was higher for the polished (assumed debonded) stem, and therefore they had concluded that either the magnitude of the stress increase was not enough to appreciably increase the damage accumulation rate or, alternatively, the polished stem did not debond immediately from the cement. Significantly (P = 0.05) more damage was initiated in the lateral cement compared to the medial cement for both kinds of surface finish. It was also concluded that, despite the higher cement stresses with debonded stems, polished prostheses do not provoke the damage accumulation failure scenario.

K.S.Katti [45] had analyzed the current state of materials systems used in total hip replacement. The author did an overview of the various material systems used in total hip replacement reported in literature. The merits and demerits of the metals, polymers, ceramics and composites were evaluated in the context of mechanical properties most suitable for total joint replacement such as a hip replacement. The current research on advanced polymeric nanocomposites and biomimetic composites as novel materials systems for bone replacement was also taken in to account.

Roy Chowdhury *et al* [119] have developed an acetabular cup of HDPE (High density polyethylene) reinforced with different percentages of kevlar and carbon fibre had been developed by compression moulding. Also they developed a walk simulator which was used for testing the tribological performance of those cups. The biocompatibility tests with those materials gave haemolysis counts well within the acceptable range and further more their results indicated a significant improvement in the biocompatibility of the polymer composites over their parent polymers.

Bufford and Goswami [21] have made a review on wear mechanisms in hip implants, they have analysed about the primary causes of premature failure in hip prostheses which are due to wear in the implants. Wear mechanisms were discussed as a function of contact stresses, lubricants and clearance, surface hardness and surface abrasions of both metal and polyethylene particulates. Also they have reviewed about the ceramics which are used in hip implants and the advantages and disadvantages of ceramics compared to other implant materials.

Pyburn and Goswami [115] have made a finite element analysis of the hip implant for representative femoral cross-section geometries and development of stress in the presence of bone cement was elucidated. Differences in cement stresses generated by varying implant cross-sections were compared with conventional features derived from representative implants. The analysis was performed under idealized implant assemblies by constraining the implant movement in the assembly. . The cross-sections and implant geometries used are generic and intended to be representative of available geometries.

Blake Latham and Goswami [19] had studied the effect of geometric parameters in this paper on the development of stress in hip implants. The parameters included: head diameter, neck diameter, and neck angle. Two three-dimensional models were drawn, one modular and one integrated implant. These models were then altered geometrically one variable at a time, and finite element analysis (FEA) was performed on the models. In total, twenty assemblies of implant/bone cement/bone were tested. Stress spectrum was drawn for each case under a combination of hip dimensions. It is shown that as the head diameter increases, the stress at a given location reduces, however, as the surface area from increased head diameter increases, the wear rate increases. Neck angle had been found to concentrate stresses in the select regions of the hip implant. In that an angle of 40 showed low stress combinations. Therefore, a particular combination offering the best performance had not been identified and constituted a part of an on going research activity in Mechanical Engineering Department at Ohio Northern University.

Sergeant and Goswami [124] had made a review analysis of the physiological effects on hip implants, they have also analysed about the Osteolysis and aseptic loosening which are the major causes of failure of total hip replacements. They have compiled the data to reflect trends in the amounts of wear

debris produced by different articulating surfaces. In this article they have overviewed the results of clinical studies, in vivo, and laboratory studies, in vitro, and provides a critical discussion of results.

McCormack *et al* [94] had done a statistical analysis of microcrack accumulation in PMMA under fatigue loading on the applications to orthopaedic implant fixation. They have modeled a statistical methodology to analyze damage accumulation in one part of a structure relative to another, and determined how one crack population was behaving relative to another. The methodology was applied to damage accumulation in the early life of hip replacements where a metal prosthesis was interlocked into the bone using polymethylmethacrylate (PMMA). They also developed physical models of the hip replacement that allowed visualisation of microcrack initiation and growth within the PMMA. Data was collected showing the growth of pre-load cracks (from pores and interfaces) and the initiation and growth of new cracks, in 10 regions of the cement mantle. Despite significant variability between the six specimens tested, it can be shown that highest damage growth rates can be correlated with specific sites in the structure. In conclusion, statistical analysis of the damage accumulation data allowed them to make definite conclusions regarding the damage accumulation behaviour in structures where microcrack growth is disperse, and when it differs widely between specimens. Models for prediction of average crack behaviour in such structures were proposed.

Xi *et al* [63] had presented a new method of shape analysis of hip joint. They have scanned bone surfaces of 12 male hip bone specimens and 26 female hipbone specimens using a 3D laser scanner. After they had performed the local and global morphology analyses on the acetabulum surface, they applied a rotation ellipsoid CAD model to fit the acetabulum surface and used an optimization technique to find the geometric parameters of the model. Also they compared the fitting error of rotation ellipsoid. From the results they found that the fitting error of rotation ellipsoid was smaller than the sphere and the rotation ellipsoid could describe the shape of the acetabulum better. They have concluded that the shape likely decreases the cases of hip joint subluxation compared to a ball and socket joint.

Simoeset *al.* [133],[31],[32] had given the design and prototype manufacture of a controlled-stiffness composite femoral prosthesis. The prosthesis is composed of a cobalt-chrome core surrounded by a flexible composite outer layer. The new design predicted performance is compared with that of conventional single-modulus prosthesis. A simple model based on composite beam theory was used to determine the optimum thickness of the composite material. The composite was made of an epoxy resin reinforced with braided hybrid carbon-glass pre-forms. The prototype was manufactured by compression moulding technique. The prosthesis developed is of having relatively high proximal-medial modulus and a lower distal modulus matching the cortical bone modulus at the prosthesis tip. To obtain very highly differentiated modulus within composite structure metal core is used along with composite material. Metal core (to give high proximal stiffness) is bonded to a reinforced polymeric composite layer (for low distal stiffness). The combination of the geometry of the core with the composite material modulus and its thickness makes it possible to obtain the pseudo-optimized stiffness. The modulus of the straight-backed stem was varied from 80GPa proximally to 20GPa distally. The modulus of the proximal medial wedge was varied from 150GPa proximally to 100GPa at the intersection with the straight-backed stem. ISO 7206 international standard provided a method to investigate *in vivo* fatigue performance of the new stem

design, reducing the risk of the implant failure. The standard 7206 part 4 details the whole testing procedure. According to standard the prosthesis has to be oriented in 10^0 in the adduction and in 9^0 in flexion and constrained at 80mm from the center of the head. The stem is plunged into saline solution, which simulates the physiological environment. The fatigue test was performed by applying a compressive sinusoidal load, ranging between 300 and 3000N, for at least 5 million cycles.

Huiskes *et al.* [61] investigated the relationship between implant flexibility and the extent of bone loss. In clinical tests it was observed that the changes in bone morphology are an effect of stress shielding and a subsequent adaptive remodeling process. The relationship was investigated using strain adaptive bone remodeling theory in combination with finite element models to simulate the bone remodeling process. The effects of stem material flexibility, bone flexibility, and bone reactivity on the process and its eventual outcomes were studied. The results sustain that the bone resorption is an effect of bone adaptation to stress shielding. The stem material flexibility affects the proximal implant/bone interface stresses. Flexible stems will reduce stress shielding and bone resorption. However, they increase proximal interface stresses.

Li *et al.* [84] had developed a numerical method to predict the progressive failure of a thick laminated composite femoral component for total hip arthroplasty. The major failure of non-cemented metallic femoral components is the component loosening and the reason for this is stress shielding. Different failure criteria and different material degradation models were incorporated as subroutines in the numerical method, which had provided the flexibility to model a wide range of materials and structures. Numerical model results were compared with that of data obtained from experiments (damage behavior of laminated composite femoral component). This work provides a ply level understanding of the damage behavior of laminated femoral component. This research is concerned with the design of fatigue resistant composite hip prosthesis. By understanding the relationship between implant design and structural responses, composite femoral components can be optimized to minimize the probability of component failure.

Baleani *et al.* [42] had investigated a theoretical protocol to predict the maximum stress induced in the stem by the ISO experimental test set-up. Stress was predicted using beam theory and FE analysis. Among them FE analysis had given more accurate results. Strain measurements were used to assess the accuracy of the theoretical calculation. Fatigue testing was performed to verify the theoretical prediction about the fatigue stem performance. Fatigue performance of hip stems has been improved with the use of high strength alloys. Investigation was carried on custom made stems made of forged Ti6Al4V titanium alloy by applying a load of 2300 N which is equal to the maximum load applied as per the ISO standards.

Kaddick *et al.* [71] had developed special routines to give the best designs of hip prosthesis before the actual production takes place. It is economical in the case of complex production processes. Stability of the carbon fibre-reinforced epoxy hip stems could be confirmed by experimental results. The risk of neck fracture was found to be one of the critical features in the design process. The mismatch of stiffness between the implant and the bone leads to stress shielding and bone resorption and is one of the contributing factors to implant failure. The two promising composite materials for endoprosthesis use are the carbon fibres with a thermoplastic PEEK or a thermoset epoxy matrix. Implants made of composite

materials are manufactured by two methods, first is by milling the structure from the thick laminated composite laminates and the second is filament winding. From a mechanical point of view main interest has to be focused on the unidirectional carbon fibre reinforced epoxy shell. The shell is filled with chopped carbon fibre core. For increasing torsional stability and to allow biological fixation by bony-ingrowth an additional layer of carbon fibres is woven onto the structure. The geometrical data were transferred as IGES file from the CAD package CATIA™. Three-dimensional patches representing the outer surface of the unidirectional shell formed the basic structure. All the finite element calculations were done using MARC® software. Three-dimensional 8-noded elements were used for the whole structure including the woven surface layer. Three different refinements were used to enable the model verification. There are 232 elements in the coarse model, 1856 elements for the medium model and finally 6264 elements for the fine one. The chopped fibre core was assumed to be an isotropic material while the shell structure had modeled by orthotropic material and *TSAI-HILL* failure criteria was used. The simulated test force was 1000N. Both the chopped fibre core and the continuous fibre shell are assumed to be perfectly bonded and without any internal defects. Real composite implants include discontinuities of the mechanical properties.

Srinivasan *et al.* [135],[136] carried out a multiscale analysis of the prosthesis made from composite materials by using 3-D global/3-D local method and developed a set of guide lines for the design of hip prosthesis made from the laminated fibre reinforced polymer composites (FRP). The need for contextual multiscale structural stress analysis in the design of laminated FRP composite femoral components is demonstrated by simulating prosthesis performance while in situ in an anatomically modeled femur. All solid and FE modeling was performed using I-DEAS. A collared non-cemented canal filling prosthesis was simulated in this study (stem diameter of 12mm, stem length of 150mm, 35mm neck length and 45° neck-shaft angle). Prosthesis was modeled in a neutral orientation within the medullary canal and assumed to be perfectly bonded to the bone within the intermedullary canal of the femur. The prosthesis was modeled with CF/PEEK composite material. Structural analysis of the composite prosthesis was carried out by ABAQUS V5.4 finite element software.

Mamatakumaripadhy *et al* [88], had done a three dimensional analysis of contact and interfacial stresses in artificial hip joint, they had also analysed the stress distribution at the zone of contact between the femoral implant and the acetabular cup and also the interfacial stress distribution at the bone-cement implant interfaces. The results obtained in the 3D analysis were compared with the experimental results. Abrupt change in stress levels were observed at the implant-cement interface because of the difference in modulus of elasticity and Poisson's ratios between the contacting materials. The mechanical debonding of cement was anticipated more in the interface of cement-implant.

Joshi *et al* [68] had done a survey of stress analyses of the femoral hip prosthesis, they had surveyed the finite element technique as applied by researchers over the past three decades, within the given limitations, to solve the complex problem. Also they had limited their paper to the analysis of the femoral component and consisted of the approximations, methodologies as reported. They had reviewed the experimental results also.

Meyer and Tichy [93] had used the finite difference approach to formulate a 3D lubrication simulation model of a total hip replacement *in vivo*. Also they tried to determine if hydrodynamic lubrication was taking place, how thick the joint fluid film was and over what percentage of two gait cycles, (walking and bicycling), the hydrodynamic lubricating action was occurring, if at all. They made assumptions of rigid surface. This was conservative in the sense that pure hydrodynamic lubrication was well known to predict thinner films than elastohydrodynamic lubrication (EHL) for the same loading. That simulation method also included addressing the angular velocity direction changes and accurate geometry configuration for the acetabular cup and femoral head components and provided a range of results for material combinations of CoCrMo-on-UHMWPE, CoCrMo-on-CoCrMo, and alumina-on-alumina components. Results were in the form of the joint fluid film pressure distributions, load components and film thicknesses of the joint fluid, for the gait cycles of walking and bicycling. The results of them had shown that hydrodynamic action occurred in only about 10% of a walking gait cycle and throughout nearly 90% of a bicycling gait. During the 10% of the walking cycle that developed hydrodynamic lubrication, the minimum fluid film thicknesses were determined to be between 0.05 μm and 1.4 μm , and occurred over 90% of the bicycling gait. Also the pressure distributions for those same periods were in the range of 2Mpa to 870Mpa for walking and 1Mpa to 24Mpa for bicycling.

Gomez *et al* [52] went for a prediction of proximal femoral fracture patterns under different loads using finite element analysis. Their main purpose of the work was to discuss the ability of finite element analyses, together with an appropriate anisotropic fracture criterion to predict the ultimate load and type of fracture in bones and more specifically in the proximal femur, they got the results of a three dimensional anisotropic criterion provides better results than other well-known isotropic criteria. The criterion parameters and the anisotropic elastic properties were defined in terms of the bone tissue microstructure, quantified by the apparent density and the so-called “fabric tensor”, whose spatial distributions were obtained by means of an anisotropic remodeling model able to capture the main features of the internal structure of long bones. They had also compared the results with the experimental work that analyzed different types of fractures induced in the proximal femur by a static overload to check the validity of them.

Wen-Chuan Chen [154] developed the Nontraumatic avascular necrosis of the femoral head (AVN) is the main indication for total hip replacement in young Chinese patients . People with a history of alcohol abuse or overdose of cortisone were predisposed to nontraumatic AVN . Although patients with nontraumatic AVN are mostly under 50 years of age, a higher prevalence of revision after total hip replacement (THR) than traumatic AVN patients was reported .Radl et al. considered that the results might be related to abnormal bone quality, which probably is accelerated by higher mechanical demand in the younger population stiffness of cancellous bone at the metaphysis in patients with nontraumatic AVN of the femoral head should be carefully considered prior to selecting a femoral stem in hip replacement surgery. The poor bone quality of nontraumatic AVN patients may result in larger micromotion after cementless THR. Therefore, a cementless, straight stem that fills the isthmus would be a better choice than an anatomic stem that is fixed at the proximal part of the canal only.

Volodymyr Pakhaliuk [151] found that the main factor contributing to prolonging the lifespan of artificial joint replacements is to reduce the wear and wear particles in the bearing couple. This is especially

important for modern total hip replacements (THR), which include the acetabular cup of ultra-high molecular weight polyethylene in combination with a metal or ceramic femoral head, because currently there is a serious trend towards younger patients who are on indications needed a hip replacement. This study is to improve the existing method of wear simulation of the bearing couple in a spherical joint of total hip prosthesis comprising a cup of ultra-high molecular weight polyethylene (UHMWPE), which is based on the solution of the contact problem using finite element analysis, taking into account the parametric dependence of wear factor on the contact pressure spherical joint of total hip prosthesis comprising a polymeric cup of UHMWPE material in combination with a metal or ceramic femoral head, based on the solution of the contact problem between them with using the finite element analysis, was improved. Such the analysis has been employed only with a constant wear factor previously. Herewith, the use in numerical studies the constant wear factors requires a certain art in the choice of the value of this factor that can always not be achieved, to obtain the reliable results. The method of this study, taking into account the parametric dependence the wear factor on the contact pressure which reflects a more realistic contact conditions was first proposed and implemented. Comparison of the computation results in terms of the cumulative linear and volumetric wear at a constant wear factor, chosen from the known literature, and as a variable parameter. Furthermore, in the laboratory of biomechanics, it is supposed to perform an experimental study of wear of the polymeric cup in a spherical joint of total hip prosthesis at the simulator, to compare the results obtained.

Lan-Feng Zhang [81] established the linear model and modified exponential model for predicting the interfacial bond stress and slip relationship between bone cement have been found in this paper. The analytical expressions of the titanium alloy stress σ_s , and the interfacial bond stress and the relative slide s are established by theoretical analysis and formula deduction. Combined with the demanding experiments data, the predicted interfacial bond stress-slip relationship have been formula deducted. . Two titanium alloy stress peaks have been found at the distance from $0.175L_a$ loading tip to $0.325L_a$ free tip, which also verified the clinical reports about stress concentration at The linear model and modified exponential model for predicting the interfacial bond stress and slip relationship between bone cement have been found in this paper. The analytical expressions of the titanium alloy stress σ_s , and the interfacial bond stress and the relative slides are established by theoretical analysis and formula deduction. Combined with the demanding experiments data, the predicted interfacial bond stress-slip relationship have been formula deducted The bond stress-slip relationship could be changed into the anchoring samples along with different positions. Two titanium alloy stress peaks have been found at the distance from $0.175L_a$ loading tip to $0.325L_a$ free tip, which also verified the clinical reports about stress concentration at the stem proximal and lateral position .

Nikolaus P [70] has carried out a Fatigue failure in the cement mantle of a simplified acetabular replacement model. The role of fatigue failure in aseptic loosening of cemented THRs has been studied extensively in femoral component. Multiple microcracks were observed with over 80% in the cement mantle. Radial cracks were observed in transverse cross-sections of implanted femora]. Finite element methods have also been used to simulate the fatigue damage accumulation in the cement mantle Stolk et al. developed a finite element algorithm that simulated creep and fatigue damage accumulation in acrylic bone cement. In this work, we present a simple multilayer model that would reproduce similar cement stress distributions as those in the cement mantle of an acetabular replacement from a plane strain FE

pelvic bone model. Cyclic loading was applied to the experimental multilayer model where a dominant radial crack was grown, as predicted by the FE analysis. High tangential stresses combined with high compressive radial stresses prompted radial crack growth in the cement mantle with characteristics of fatigue damage. Although the stress distributions from these 2D models are similar to those from 3D models, the magnitudes are much greater hence the form of fatigue damage in 2D models may not be necessarily representative of that found 3D models.

VesaSaikko [148] went for a prediction that If the wear rate of ultrahigh molecular weight polyethylene (UHMWPE) components of prosthetic joints is high, themicroscopicUHMWPEwear particles that are produced in large numbers are known to cause osteolysis Ultrahigh molecular weight polyethylene (UHMWPE) is the most popular bearing material in prosthetic joints due to its chemical inertness, wear resistance, resilience, impact strength, and machinability .Unfortunately, the UHMWPE wear particles produced clinically are mostly in the size range of 0.1 μm to 10 μm whichmakes them biologically most active. In scanning electron microscopy, there was a marked difference in the number and size of UHMWPE wear particles between hip and knee wear simulation. The diameter of the hip wear particles was $0.30 \mu\text{m} \pm 0.15 \mu\text{m}$ ($n = 170$). They could be observed in abundance Knee wear particles were few in number ,and their diameter was on the average five-fold larger, $1.53 \mu\text{m} \pm 0.89 \mu\text{m}$ ($n = 113$). In both categories, the mean aspect ratio was close to unity which justified the method of determining the diameter.

P. Kouyoumdjian [79] had done the evaluation of hip joint rotation range of motion in adults. Internal (IR) and external (ER) rotation of the coxo femoraljoint play a central role in the combined rotation of theleg and the pelvis during walking and during variousother activities of daily life. For reliability and reproducibility the same protocol was performed on all subjects, in the same room and in the same way. Hip rotation ROM values were calculated with the patient in three positions • position 1: dorsal decubitus (DD) (hip in flexion at 0° and knee at 90°); • position 2: ventral decubitus (VD) (hip in flexion at 0° and knee at 90°); • position 3: seated (hip in flexion at 90° and knee at 90°). Total hip rotation ROM (TAR) was 68.1° in position 1, 77.1° in position 2 and 78.5° in position 3. Distribution was normalin all positions except for the TAR in position 1. Hip rotation ROM values in the different positions were in position 1, IR = 29.6° , ER = 38.5° , in position 2, IR = 35.2° , ER = 41.8° , and in position 3, IR = 37.9° , ER = 40.7° . Mean hip rotation ROM balance (EqRm) between IR and ER in position 1 was 7.83° of ER (SD: 13.98°), in position 2, 6.63° of ER (SD: 19.43°), and in position 3, 2.85° of ER (SD: 11.33°). There was no significant difference in TAR values, ER, IR or EqRm in the different positions.

Ramachandran Prabhakar [116] had studied the use of RapidArc techniques in the treatment of prostate cancer patients with hip prosthesis. High density material poses significant problem to the incident or exiting beam. These materials not only attenuate the treatment beam but also scatter the dose which may lead to dosimetric uncertainty at the soft tissue interfaces. Hence, it becomes a challenging task to achieve dose uniformity inside the PTV for these patients who undergo radiotherapy. Hence, in this study, an effort has been made to demonstrate the use of volumetric modulated arc therapy for prostate patients presenting with hip prosthesis. This study shows that RapidArc technique with double arcs is a simple and effective treatment method in case of patients presenting with hip prosthesis. The use of a beam

avoidance structure encompassing the prosthesis and applying strict dose constraints reduces the beam contribution to the prosthesis.

J. Okrajni [103] evaluated the computer modelling methods presented in the paper together with the analytical approach are of great importance to both forecasting the implants' behavior during a surgical procedure and in their operational conditions, as they'll as in the selection and modification process of surgical cements' material properties. The physical laboratory models should constitute the main validation method for computer models. The work presents only one of many aspect of the biomaterials' influence on the phenomena taking place in organs with implants i.e. heat flow in the artificial hip joint with cements' fixation of the stem. In future it will be necessary, for instance, take into account the interface layer properties and mechanical features of cement as the polymer with its typical creep behavior or shrinkage of the material during the polymerisation process.

RSM Ling FRCS [75] presented a long-term follow-up report of the results of the original Exeter polished cemented stems inserted between November 1970 and the end of 1975 at their institution by surgeons of widely differing experience, utilising crude cementing techniques. The results of this series were reported in 1988 [1] and again in 1993 [2]. There have been no failures from aseptic femoral component loosening since the 1993 report. From the original series of 433 hips there were, at the end of 2003, 26 living patients with 33 hips. Of the latter, there were 25 hips in 20 patients with their original femoral components still in situ. 28 hips (6.46%) from the original series have been lost to follow-up, though none since 1992. With the end-point re-operation for aseptic stem loosening, the survivorship is 93.5% (95% CI: 90.0% to 97.0%). The re-operation rate for aseptic femoral component loosening is 3.23% into the 33rd year of follow-up.

S.H. Teoh [76] studied that the Fatigue fracture and they have been identified as some of the major problems associated with implant failure of medical devices. The actual in vivo mechanisms are complex and involve the hostile body environment. The response of the host tissue to the debris is a real issue. Fatigue-corrosion and environmental stress cracking are common. Although fatigue fracture and they are frequently reported in orthopaedic applications such as hip joint prostheses, they can be fatal in mechanical heart valves. While it is not possible to avoid failure, recent work has focused on predictive tools to enable more accurate prediction so as to avoid catastrophic failure in vivo. This paper presents an overview of fatigue fracture problems in metallic, polymeric and ceramic implant materials, looks at some recent techniques of testing and discusses the future development of fracture and debris resistant biomaterials.

Sathya Ganapathi [125] performed the design and analysis of a hip implant using Finite element analysis. Fracture conditions are determined and the optimal design of the implant is obtained for improving healthcare and patient safety. Anthropometric parameters of the human femur bone are collected from a particular age group. These are then used to obtain a CAD model of the bone using CATIA. The standard Charnley hip implant, used in total hip replacement surgery is also modeled. The proposed models are analyzed using ANSYS software by assigning appropriate material properties to the bone and implant. The stress distribution is observed when loads corresponding to normal gait conditions are applied. The load at which fracture occurs is then determined experimentally. Based on the analysis results of the

modelled bone, the implant is optimized by varying the base cross section, the bio-materials used, and the design parameters so that, its stress response mimics that of the actual bone. It is found that the model no 2 as in Table 6 with head diameter 28mm, neck diameter 10mm, neck angle 128 degrees has minimum strain at the neck region with a value of 0.65 and is found to be suitable for implant design. Results show that initiation of fracture in the implant occurs at 2000N and complete fracture occurs at 2400N. The 3D models are very useful in simulation of bone fractures and internal fixations with implants. In this work, the hip joint and implant model, developed in CATIA software, help to understand how these structures adapt to external forces disturbances. This will help the doctors to choose the optimal implant for a particular patient. This leads to greater accuracy and patient specificity.

M. DI MONACO [39] aim this paper was to systematically review the controlled trials published on the effectiveness of physical exercise programs after THA. Nine studies theyre retrieved from MEDLINE and revietheyd. Results show that the physical exercise protocols most frequently used after THA in the early postoperative phase are neither supported nor denied by clinical controlled trials. Convincing evidence for the effectiveness of single interventions in addition to usual exercise programs exists for each of the three following options: treadmill training with partial bodytheyight support, unilateral resistance training of the quadriceps muscle (operated side), and arm-interval exercises with an arm ergometer. In the late postoperative phase (operation interval > 8 theyeks) exercise programs consistently improve both impairment and ability to function. Theyight-bearing exercises with hip-abductor eccentric strengthening may be the crucial component of the late-phase protocols. Substantial limitations theyre found in the nine studies, including small sample size, patient selection, heterogeneity of outcome assessments, and potential stheirces of variability not investigated. Despite limitations, they conclude that three main suggestions emerge from controlled trials on physical exercise after THA: early postoperative protocols shouldinclude additive interventions whose effectiveness has been shown. Late postoperative programs are useful and should comprise theyight-bearing exercises with hipabductor eccentric strengthening.

Gianluca Mario Izzo [51] studies aim to develop a monitoring techniques based on Gait analysis and bone density changes to assess patient recovery after Total Hip Arthroplasty. Furthermore, to validate computational processes based on 3D modeling and Finite Element Methods for optimizing decision making in the operation process and selecting the suited surgical procedure. A vision could be minimizing risk of periprosthetic fracture during and after surgery. Patients: The sample presents 11 patients receiving cemented implant and 13 for the uncemented. Patients are grouped by type of implant. Three checkpoints theyre considered: before, after operation and one year later. CT scans, gaitrite and kinepro measurements have been realized. Main outcome measures: Fracture risk probability is higher in bone with low bone mineral density; therefore bones are more fragile in elderly people. BMD is indeed one parameter considered among all the observations. Periprosthetic fracture of the femur is a rare but complex complication of THA, and requires demanding surgery. As such, they result in considerable morbidity and dysfunction. Thus, tests of force reaction have been accomplished to support surgeons during the prosthesis fitting. Identification of risk factors for fracture will improve preoperative counseling and aid primary prevention. To assess eventual improvements or find out trends respecting the implant used, gait data have been collected and compared with muscles mass modeling.

B. Jaramaz [65] made a study on Dislocation following total hip replacement surgery represents a significant cause of early failure, incurring additional medical costs. The causes of dislocation are multifactorial and are related to surgical approach, soft tissue tension, prosthetic design, and most important, orientation of components. This paper describes experimental verification of their analytical approach for predicting implant impingement and dislocation. Once fully developed and tested, this analytical methodology could be used as a preoperative simulation tool that will present surgeons with information about the "safe" range of motion and chance of dislocation based on selected component positions, allowing for the surgical plan to be optimized based on this criterion. Coupled with a computer-assisted clinical system for precise implant positioning, this approach could significantly reduce the postoperative risk of dislocation, maximize "safe" range of motion and minimize impingement.

Monika Michalíková [96] had made Pre-operative planning is a very important part of hip arthroplasty (especially reimplantation of total hip and hip joint). Conventional pre-operative planning is realized with caliper, protractor, plastic transparent templates and x-ray images. This conventional templating technique is time consuming with many errors and impractical. This paper presents the current applications of computer technology in the field of surgery and preoperative planning of total hip implantation. At the present time, orthopaedic surgeons use transparent template radiographs as part of pre-operative planning in order to gauge the suitability and correct size of an implant. The newly developed CoXaM software offers a simple solution to the problems by using digital x-ray images and handmade transparent plastic templates. The utilization of developed software has many advantages in the hospital unit (the elimination of storing large inventories of implants, the minimalization of errors from the magnification of templates and x-ray images, etc.). The proposed methodology provides the opportunity for comfortable, user-friendly and dimensionally accurate computer programming surgical operation. The technique is reliable, cost effective and acceptable to patients and radiographers.

Mary O'Sullivan [89] made a study as Little is known on the nursing contributions to the mobilising of older adults following hip replacement surgery. This paper presents the findings from a study on nurses' views of the contributions they make to the mobilising of older patients recovering from total hip replacement. A specific focus was laid on pain management and interpersonal care. The results show that Irish nurses reject mechanistic models of care in favour of contemporary approaches. The work of other authors is discussed extensively. Current demographic trends represent an increase in the older population in Ireland. Increased longevity influences expectations regarding the quality of life. The increasing numbers of the older adults undergoing joint replacement surgery is testimony to the prevalence of degenerative joint conditions among this population. However, a period of adaptation follows surgery and is when the patient's physical, psychological and social functioning is restored. The adoption of an enabling person-centered approach to rehabilitation is consistent with the philosophy of care of older adults.

Stuart Kerrigan [139] revealed in this paper they propose a new method for the measurement of theyar of a total hip replacement. Their method exhibits a greater degree of automation and is to be both accurate and repeatable. Measurement of theyar can be quantified as the displacement of the centre of the femoral head relative to the centre of the acetabular cup or acetabular rim. Their method uses active ellipses - ellipses that, with prior knowledge of the intended contour, search for and alter shape to segment the boundary

of the head and rim. A set of radiographs are manually annotated and the characteristics of the boundary of the femoral head and acetabular rim are learned. Two ellipses are sequentially placed on the radiograph, the first deforming around the boundary of the femoral head, the second placed using the previously learned average shape of the acetabular rim and converges around the wire marker. Once both ellipses have converged the distance between their two centres can be calculated and converted to mm as a measure of theyar. Their method is validated by comparison with manual fitting of ellipses. A discussion of the results, the clinical relevance and further investigations concludes this paper.

Jessica Williams [67] made an study in radiography remains the mainstay of imaging evaluation of hip arthroplasties, with an AP pelvic radiograph the common protocol in the post operative setting. It is imperative that post operative radiographs are of high diagnostic quality with the patient non rotated, supine, hips in extension and 15° internal rotation. The centre of the x-ray beam needs to be focused on the pubic symphysis to ensure the inclusion of the entire hip prosthesis and cement. The literature unanimously agrees that there are five key elements which should be evaluated in order to determine if initial component positioning and fixation is adequate. These include leg length, horizontal centre of rotation, acetabular inclination, femoral stem positioning and assessment of the cement mantle .This article provides a systematic framework for radiographers to assess and evaluate the quality of a hip arthroplasties and highlights the need for high quality diagnostic radiography.

Sandesh Reddy Yaratapalli [122] analysed the functional and radiological outcome of total hip arthroplasty done for non traumatic indications. 31 patients who had 38 cemented (or) uncemented hip prosthesis they are follotheyd retrospectively and prospectively for 5-13 yrs. A cemented prosthesis was used in men older than 60 yrs and women older than 55yrs and in younger patients in whom adequate initial fixation could not be obtained without cement. Uncemented implants theyre used in all other patients. They used the Harris hip score (Modified) for clinical and functional evaluation and plain x-ray pelvis with both hips and proximal femur - AP view and x-ray of the operated hip -lateral view for radiological evaluation. All the patients theyrefollotheyd up at Immediate Postop, 6wks, 3mths, 6mths, 1 year and annually thereafter. The mean HHS at latest follow up of both cemented and uncemented THR was 88 and 89 respectively. On analyzing the difference in pre op and latest HHS for various nontraumatic indications, their study shotheyd that the results theyre better in patients with AVN follotheyd by OA and RA. In their series of Uncemented THR s they have 95% excellent/good results while in case of cemented THR s they have 82% excellent/good results. The Harris hip score is a very useful scoring system in assessing total hip replacement done for non traumatic indications and shotheyd high validity and reliability. The results in patients with avascular necrosis and osteoarthritis theyre significantly better than those with rheumatoid arthritis. Uncemented and cemented THR give equally good results in non traumatic indications.

syedzameer [142] found that the fatigue analysis is used to compute the fatigue life at one location in a structure. For multiple locations the process is repeated using geometry information applicable for each locations. Necessary inputs for the fatigue analysis are shown in Fig. The three input information boxes are descriptions of the material properties, loading history and local geometry. All of these inputs are discussed in following sections. In the present work, considering **Ti-6Al-4V and Al2O3 Ceramic**

Composites as the materials for the cemented type hip prosthesis, the fatigue life of these hip prosthesis will be determined for five different daily living activities viz., slow walking, fast walking, normal walking, sitting and standing. Fatigue calculations have been carried out using Goodman, Soderberg, and Gerber fatigue theories. The stress analysis for different activities will be carried out using finite element software ANSYS and then the fatigue analysis is performed using residual degradation model.

5.INTERFACIAL STRESSES AND MATERIAL SELECTION

Literature review on FE analysis includes the various design considerations and the application of design optimization. There are various design considerations, which eventually affect the stability and the long-term applications are discussed in this context. The interfacial stresses are the main reason for the implant micro motions and finally leads to implant loosening. This will be avoided by reducing the interfacial stresses.

George Grammatopoulos [50] observed that femoral fractures are a recognised complication following hip arthroplasty, occurring in 0.1–6% of all patients with a total hip replacement. The incidence of such fractures is increasing due to the ageing population and the increased number of primary and revision hip arthroplasty. Femoral peri-prosthetic fractures are a challenging and difficult complication to treat, evidenced by the numerous treatment modalities and techniques described in the literature. Lowenhielm reported the importance of prosthesis design in the development of proximal or distal femoral fractures. Lindahl noted that straight, non-anatomic, shorter cemented stems were associated with a higher fracture risk, possibly due to the difficulty in positioning a straight stem, achieving an adequate cement mantle and preventing subsequent loosening. In conclusion, they identified a common fracture pattern around PTC stems, the extent of which can be underestimated preoperatively using standard radiographs. This fracture pattern requires extensive reconstruction surgery invariably with revision of the existing hip replacement with possible supplemental fixation and allograft.

J. Beldame [11] found that total hip arthroplasty (THA) with metal-polyethylene coupling remains the standard despite osteolysis induced by polyethylene wear, the main cause of long-term failure. With the objective of diminishing wear debris, Weber re-introduced metal-on-metal coupling in the form of a cemented sandwich for the cup (Cr-Co Metasul™ insert set in a polyethylene cup covered with steel mesh on its peripheral face) paired with a Metasul™ femoral head (original forged chrome-cobalt Cr-6 Co-28 Mo-0.2C) (high carbon percentage). Study confirms the good mid-term clinical and radiological results of hip prostheses series with metal-on-metal Metasul™ type bearings and non-cemented cups, in young patients, despite two femoral implant ruptures and a high infection rate (2.8%). The rates of aseptic loosening, RLL or acetabular osteolysis are low and stable in time, contrary to Metasul™ series with polyethylene directly cemented in bone or ceramic-on-ceramic coupling series with cemented cups. Our survival rate is also comparable to those of hard-hard coupling with non-cemented cups.

Bertani [17] discovered that the Management of extensive proximal segmental femoral bone loss secondary to tumor resection or major osteolysis remains controversial. Historically, the first

reconstructions used allograft. Failure rates were high, due to typical allograft complications: infection, bone resorption, fracture and graft non-union . The alternative attitude is prosthetic hip replacement, either by composite prosthesis (encased in an allograft) or by megaprosthesis. The JVC IXTM stem is a femoral stem with collar, of constant length, giving a 200mm anchorage in the distal femur. It is sealed using **methyl methacrylate**. Severe proximal femoral bone-loss creates a difficult situation with no ideal treatment option. While the distal anchorage is the real weak point in reconstruction prostheses, the present study uncovered no sure loosening of the femoral stem at a mean 5.4 years' follow-up. Modularity optimized adaptation to the precise bone-loss, whatever the context (tumor or revision surgery). Modular megaprotheses represent a salvage solution, with encouraging medium-term results. They seem ideally indicated for extensive proximal femoral bone-loss in patients with limited life expectancy.

P. Abadie[1] found that Implanting a hip prosthesis into a bone site, whether the acetabular cavity or the femoral shaft, constitutes a mechanical aggression liable to disturb bone metabolism equilibrium and physiological bone aging. Over the medium term, a new biological equilibrium is established, depending on the mechanical properties of the alloy of the implant, its shape and relationship to the bone and the resultant stress pattern . Thus, implanted femurs evolve under the influence of mechanical, physiological and biological factors . Bone-remodeling is not specific to cementless total hip implants, and the present study investigated its occurrence with cemented models. Over five years' follow-up, remodelling was visible only on X-ray, with no clinical impact whatever its form (spongialization, or grade 1 or 2 stressshielding). The sole factor correlating with stress-shielding in this series comparing DédicaceTM and MK3TM stems was the degree of filling at the distal third of the stem. Metaphyseal filling was comparable with both models, and did not correlate with stress-shielding. Rigidity, shape and stem coating were the factors determining femoral adaptation and lasting fixation.

C. Delaunay [38] studied that those who may have been exposed to the metals, in particular, foundry workers in industry. Patients with Co-Cr metal-on-metal bearings are exposed to wear with liberation of cobalt and chromium into the synovial fluid. There are two techniques discussed here : graphite furnace atomic absorption spectrometry (AAS) and inductively coupled plasma/mass spectrometer (ICP/MS). The cobalt and chromium results are expressed either in nanomoles (international units) or more generally in micrograms/liter. Cobalt's molar mass is 58.8 g (59 g) and chromium's is 51.9 g (52 g). The assessment of cobalt and chromium is sensitive, accurate and reproducible. The rate of circulating Co and Cr ions is low when the bearing couple functions well ($Co < 1 \mu\text{g/L}$). Hypersensitivity is idiosyncratic, unpredictable with cutaneous tests, specific to metal-on-metal couples, and apparently rare: 0.3%. Metal-on-metal bearing couple surfaces allow the surgeon to increase the size of the femoral head in THA. This is advantageous from a number of points of view, in particular for joint stability and to prevent component impingement.

A. Cogan [30] revealed that Hard-on-hard bearing surface have been accepted as a valuable alternative for young and active patients needing a hip replacement because these combinations are resistant to wear. Alumina-on-alumina bearings have been accepted as a valuable alternative for young and active patients. Alumina fractures, and socket loosening were the main complications reported. But, with the increasing

number of prostheses implanted, noise occurrence appeared as a new concern. The primary aim of the present study was to quantify the prevalence of noticing noise in a population having received alumina-on-alumina total hip arthroplasty as well as its eventual impact on outcome. Noise generation after hip arthroplasty seldom has been reported before the end of the 2000s decade. Most of the recent reports focus on hard-on-hard bearings. The current series demonstrated that 10.6% of the hips generated some sort of noise with alumina-on-alumina hip arthroplasty. The strengths of the present work are that it was a systematic survey that was specifically constructed to answer the question of noise occurrence, the rate of hips lost to followup remain within an acceptable range (6.7%), a single model of hip arthroplasty delivered by a single manufacturer was used, the characteristics of the material were well understood and controlled.

A. Shapi'i [130] discovered that Preoperative templating in Total Hip Replacement (THR) is a method to estimate the optimal size and position of the implant. Today, observational (manual) size recognition techniques are still used to find a suitable implant for the patient. Therefore, a digital and automated technique should be developed so that the implant size recognition process can be effectively implemented. For this purpose, they have introduced the new technique for acetabular implant size recognition. Preoperative templating has been useful to determine the optimum implant size in total hip replacement (THR). With classical tracing paper now obsolete, they have developed a new technique to undertake the templating procedure with a digital acetabular implant and an X-ray. The digital implant provides several advantages for THR surgery. Compared to the observational method in which the surgeon uses a template manually and places it on the patient's X-ray, the use of the digital implant not only saves time, but also can reduce the error due to consistency difference when making adjustments to a patient's implant size.

PrösturPétursson [145] is performed with or without the use of bone cement. The lack of reliable clinical guidelines for deciding which one to implement has encouraged this approach of joint clinical and engineering with the following objectives: 1. Validate quadriceps muscles and femur bone atrophy by extracting the mineral density from Computer Tomographic (CT) images. 2. Validate computational processes based on 3-D modeling and Finite Element Methods (FEM). A clinical trial was started, where 36 volunteer patients underwent THA surgery for the first time: 18 receiving cemented implant and 18 receiving uncemented implant. The patients were CT scanned prior-, immediately after and 12 months post-surgery. The CT data are further processed to segment muscles and bones and to create 3D-models for the simulation and for calculating bone mineral density (BMD). Furthermore quadriceps muscle density Hounsfield (HU) based value is calculated from the segmented file on healthy and operated leg. These preliminary results indicate computational tools and methods that are able to quantitatively analyse patient's condition pre and post-surgery. The BMD and muscle density measurement in correlation with the fracture risk analysis display a potential method for eligibility to receive non-cemented implant; the preliminary results show that also elderly that according with current clinical evaluation receives a cemented implant are suitable for the non-cemented type. The risk for structural failure during THA surgery is estimated by calculating femoral bone fracture risk index (FRI) as a ratio between compressive

stress during surgery and estimated failure stress on bone. The correlations with the BMD observations during the clinical trial will assess and validate this potential predictor tool.

6. LUBRICATION, WEAR AND FRICTION IN JOINTS

L. Mattei [90] reviewed the lubrication and wear models of hip implants published in the last few years. An accurate description both of methods and results is reported, stressing simplifying hypothesis and models input data to make their comparison easier. It is pointed out that actually lubrication and wear are described neglecting each other while new advanced models including both aspects could be helpful. Theoretical modelling of hip implant lubrication has been extensively investigated in the literature in the last few years, evolving towards the simulation of the rather complex in-vivo conditions. In order to better classify and compare the main studies, a preliminary description of the major features of the problem and of the models is premised. It can be pointed out that both in lubrication and wear a distinction is made between models for soft-on-hard material couples, mainly MoP, and hard-on-hard implants, as MoM or CoC. The present review can be useful to compare different wear and lubrication models and their results in order to evidence their reliability and limits and consequently plan specific studies for improving theoretical modelling that can help in the development of hip implants with higher performances and longer life.

Philipp Damm [110] measured the Friction in Total Hip Joint Prosthesis during Walking. The Joint forces and friction moments were measured in vivo using instrumented hip implants. The prosthesis (CTW, Merete Medical, Berlin, Germany) is based on a clinically successful implant with a titanium stem, a 32 mm Al₂O₃ ceramic head and a XPE inlay. A telemetry circuit, six-strain gauges and an induction coil are arranged in the hollow neck. The resultant contact force (F) and the resultant friction moment (M) are calculated from their three components (F_x, F_y, and F_z). Because the force component in direction of the femoral axis always acts downwards, F_z points toward the center of the implant head. It was shown that the peak values of the in vivo acting friction moments during walking were smaller than critical torsion torque at the cup-bone interface. However, higher friction moments can be expected during high demanding activities, which might be critical for the cup fixation, especially shortly after implantation. This study has reported for the first time post operative changes and the individual differences of the in vivo forces and friction moments acting in total hip joint replacements. These in vivo loads can now be used as realistic input data for friction and wear simulator studies.

Claire Brockett [27] had investigated a Friction of Total Hip Replacements With Different Bearings and Loading Conditions. This study has examined the friction of total hip replacements with a fixed 28 mm diameter, manufactured from different materials. Friction measurements may be used to determine the lubricating mechanism prevalent within the implant. Although friction no longer appears to be a major factor in implant failure, a low friction factor indicates improved lubrication, which may result in lowered wear. Measurement of friction is a useful tool for evaluating the tribological performance of replacement bearings. Previous studies have shown friction to be dependent upon several factors. Wang et al. [32] examined the influence of contact stress upon the friction of MoP implants, under serum-lubricated conditions, and found the friction factor varied with clearance and peak load. A reduction in friction factor was seen to occur with increased contact stress, resultant from either increased radial clearance or

increased peak load. This study showed that test conditions, such as swing phase load and lubricant, may have a substantial effect upon the outcome of the friction study, hence it is important to evaluate this information when comparing materials or implant design.

N. Passuti [105] had given the Friction couples in total hip replacement . Metal—metal couples also display very good tribological behavior, but at the cost of the formation of Co and Cr ions impacting surrounding bone tissue and accumulating in remote organs. The behavior of such “hard—hard” couples greatly depends on implant component positioning and on the consequences of repeated neck-insert contact. Very highly crosslinked polyethylene (PE) shows very significant improvement in terms of wear at five years’ follow-up compared to conventional PE, but the behavior of this new concept will need to be monitored in the clinical situation if the disappointments experienced with previous hylamer-type improved PE are to be avoided. Friction couples pose as yet unsolved problems, and the optimal choice depends upon the patient’s age, level of activity and functional requirements: risk—benefit information for each material must be clear. Innovation in techniques is needed, but only given prospective studies of more than five years’ FU. Biology enables very early screening for osteolysis liable to respond to specific medical treatments. Orthopedic surgeons need to be eclectic in their choice, adapting the friction couple indication to the age and activity level of the patient.

Susan C. Scholes and Thomas J. Joyce [141] studied that THR is seen as one of the most successful orthopaedic operations available today. There are currently over 80,000 hip replacement procedures carried out in England and Wales each year and THR has now become more popular with the younger, more active patient. This is shown in the statistics reported in the National Joint Registry; 12% of the patients who undergo THR are under the age of 55 and 85% of these are recorded as being either fit and healthy (16%) or with mild disease that is not incapacitating (69%) . However, failure of these artificial joints does occur, leading to the need for revision surgery; approximately 10% of the THR procedures reported are revision operations . From the results reported here it is clear that ceramic-on-ceramic hip joints have good tribological results: low friction, good lubrication and very low wear *in vitro* and *in vivo*. In addition to this, ceramic particles are biologically inert. Also, the fracture risk is relatively low. With good implant positioning these joints have the potential to perform incredibly well. These bearings, therefore, deserve to be high on the list for both primary and revision implants, especially for the younger, more active patient. However, for the best results, the choice of bearing combination design should be patient-specific; as one design does not suit all.

Azrulhizam Shapii [8] had used Pre-operative planning procedures which plays an important role in determining the size of the implant to be used in total hip arthroplasty surgery (THA). In this research, a new implant detection algorithm has been developed to do an automated templating process using digital CPT implants and digital X-ray images. The new algorithm provides a simple solution to overcoming the problems faced by orthopaedic specialists when using conventional methods during the implant templating process for THA. This algorithm allows the orthopaedic specialist to choose the CPT digital implant automatically in pre-operative planning. One of the advantages of using the digital automated algorithm in pre-operative planning is that an X-ray image (film) is no longer required and this can reduce the risk of losing a patient’s X-ray images [5]. In addition, by using the new implant size

detection algorithm, orthopaedic specialists can make an accurate and quick decision during the selection of the CPT implant size for patients.

H. Kapstad R.N [74] identified the Changes in pain, stiffness and physical function in patients with osteoarthritis waiting for hip or knee joint replacement surgery. Patients with OA experience increasing pain and progressive loss of function, particularly in walking and stair climbing. Joint replacement surgery of the hip or knee is a commonly used, effective intervention for severe OA. The decision to proceed with joint replacement surgery is based on radiographical findings, physical examination of the joint, and the patient's subjective symptom. In the present study, patients with OA of the hip did not change significantly in pain, stiffness or physical function, as assessed with the WOMAC scales, while waiting for hip replacement surgery. In contrast, patients with OA of the knee experienced deterioration on the physical function scale, but not on the pain subscales, while there was a nonsignificant tendency to deterioration on the stiffness and total scales of the WOMAC. However, the mean change among knee patients on the physical function scale of 0.3 units was less than a change of 10%, which is commonly considered a clinically important difference on the WOMAC scales. Moreover this change was about 0.2 SD, which is less than the 0.5 SD frequently cited as an important change with some other health status instruments.

Catarina A. Oliveira [22] diagnosed the patients with metal-on-metal prostheses and he had done the evaluation of a prosthetic implant should always be preceded by the knowledge of the type of implant. Each of them has a different imaging appearance and different associated risk complications. Complications manifesting as dense areas are rare and have a narrow differential diagnosis. Most frequent are heterotopic ossification and cement extravasation [1]. Cement extravasation was excluded in this case, because this was a cementless prosthesis. Heterotopic ossification occurs when primitive mesenchymal cells in the surrounding soft tissues are transformed into osteoblastic cells and form mature bone. It typically occurs around the femoral neck and adjacent to the greater trochanter in 15–50% of patients. Many patients with low-grade heterotopic ossification are asymptomatic. Articular stiffness and pain are the main clinical complaints. Metallosis was first described in association with setting of the fixation of fractures with metal implants. The adoption of articular components made of other materials such as polyethylene or ceramic has dramatically reduced its incidence in patients with articular prostheses, and nowadays it is a rare complication (5.3% of total hip arthroplasty complications). Although less frequent, even with polyethylene or ceramic articular components metallosis can occur if there is abnormal metal-on-metal contact due to wear or fracture of the articular component.

Brockett, C.L., [28] studied that Large diameter metal-on-metal bearings are becoming increasingly popular, addressing the needs of young and more active patients. Clinical data has shown excellent short to mid-term results, though incidences of transient squeaking have been noted between implantation and 2 years post-operative. Material choice and geometric design features, such as clearance, have been significant in influencing the performance of the bearings. Three different clearance bearings were investigated in this study using a hip friction simulator to examine the influence of clearance on friction, lubrication and squeaking. The friction factor was found to be highest in the large clearance bearings under all test conditions. The incidence of squeaking was also highest in the large clearance bearings, with all bearings squeaking throughout the study. A very low incidence of squeaking was observed within

the other two clearance groups. The lubricating film was measured using an ultrasound reflection method and was found to be lowest in the large clearance bearings. This study suggests that increasing the bearing clearance results in reduced lubricant film thickness, increased friction and an increased incidence of squeaking.

Vinod Pallapu[149] made study on the wear of acetabular cup in Metal-on-Metal implant is estimated and a means of reducing the wear by using functionally graded materials is addressed. The contact pressure is obtained through finite element tool (Ansys) and the wear is obtained by Archard equation from the contact pressures obtained by Ansys. The contact pressures and wear is estimated for both Metal-on-Metal hip implant as well as implant coated with functionally graded material and the results are compared. The contact pressures are obtained for various loads and orientation of femoral head and acetabular cup according to a 3 dimensional gait cycle. The gait pattern associated with normal walking of human at 4 km/hr is considered for analysis. It was found that the maximum hip load in the gait cycle was about 230% of the body weight of the patient. This gait cycle is divided into 8 instances .It is shown in this work that the linear wear for functionally graded implants are far lesser than Metal-on-Metal implants commercially used today.

K.Ch. WIERZCHOLSKI [155] presented this paper on various kinds of friction forces occurring in a human joint gap. Some main factors which can change the friction forces in a human joint are indicated. Friction forces for squeezing, boosted squeezing and weeping in macro, micro and nano level for porous cartilage are presented here. According to the author's knowledge the problem of human joint lubrication in unsteady motion has not been hitherto considered in scientific papers on bio-tribology. friction forces in spherical and other curvilinear orthogonal co-ordinates for hydrodynamic steady and unsteady unsymmetrical synovial non-Newtonian fluid flow with variable viscosity and for random changes of human hip joint gap. In this paper are presented the analytical solutions of various kinds of the friction forces occurring in of human joints gap and in pores of cartilage joint caused by: hydrodynamic lubrication by rotation, by squeezing, boosted squeezing and weeping. Permeable phenomena of the synovial fluid inside cartilage pores are taken into account.

Claire Brockett [26] made an Metal-on-ultra-high molecular weight polyethylene (UHMWPE) total hip replacements have been the most popular and clinically successful implants to date. However, it is well documented that the wear debris from these prostheses contributes to osteolysis and ultimate failure of the prosthesis, hence alternative materials have been sought. A range of 28 mm diameter bearings were investigated using a hip friction simulator, including conventional material combinations such as metal-on-UHMWPE, ceramic-on-ceramic (CoC), and metal-onmetal (MoM), as well as novel ceramic-on-metal (CoM) pairings. Studies were performed under different swing-phase load and lubricant conditions. The friction factors were lowest in the ceramic bearings, with the CoC bearing having the lowest friction factor in all conditions. CoM bearings also had low friction factors compared with MoM, and the trends were similar to CoC bearings for all test conditions. Increasing swing phase load was shown to cause an increase in friction factor in all tests. Increased serum concentration resulted in increased friction factor in all material combinations, except MoM, where increased serum concentration produced a significant reduction in friction factor.

JOSHUA J. JACOBS [69] reviewed the focuses on electrochemical corrosion phenomena in alloys used for orthopaedic implants. A summary of basic electrochemistry is followed by a discussion of retrieval studies of the response of the implant to the host environment and the response of local tissue to implant corrosion products. We recently performed a postmortem examination of a subject who had been enrolled in a prospective study of metal-ion release in association with primary total hip replacement⁴⁷, so both longitudinal concentrations of metal in the serum as well as concentrations in remote tissue could be measured. Markedly increased levels of titanium, aluminum, and vanadium were found in the periprosthetic (local) tissue; increased levels of titanium also were found in the spleen. However, the concentrations of titanium and aluminum in the serum had not increased over the three-year study period. Thus, even in the absence of an increase in the level of metal in the serum, deposition of metal can occur locally and in remote organ stores in association with a well functioning device.

MyoMinn [99] found that the poly(etheretherketone) (PEEK) is a high strength and high temperature engineering polymer. However, its tribological performance is not very good in its pure form unless fillers or fibers are added to form composites. As polymers are often used for applications where traditional oil based lubrication may become an issue, water-based lubrication is desirable. This paper explores the lubrication performance of a natural fibrinolytic enzyme, nattokinase, found in fermented soybean (natto) in aqueous solution. Pins of PEEK were slid against a steel disk in a pin-on-disk tester with the aqueous lubrication. The counterface disk material was a tool steel ($R_a = 0.37 \mu\text{m}$). Tests were conducted at a rotational speed of 100 rpm and a normal load of 80 N. For comparison, tests were also conducted in NaCl solution. Nattokinase aqueous solution provides a coefficient of friction between PEEK and steel of 0.2 as compared to 0.3- 0.35 for dry condition. The specific wear rates of PEEK for dry, deionized water, NaCl solution and aqueous nattokinase solution conditions were 10.5×10^{-6} , 51.6×10^{-6} , 228×10^{-6} and $8.8 \times 10^{-6} \text{ mm}^3/\text{N.m}$, respectively. The fibrinolyticnattokinase enzyme provides lubricity with alkalinity reducing corrosion and eventually reducing wear.

7.COMPARISION OF CEMENTED ,HYBRID AND CEMENTLESS STRUCTURE.

Andrew P. Foster [5] had made a study showing that the risk of periprosthetic femoral fracture is significantly greater with use of the cementless AMP in the management of displaced intracapsular femoral neck fractures. Bone cement may act to reinforce the proximal femur, improve load distribution and hence protect against shaft fracture. This may explain the low incidence of periprosthetic fracture with cemented prostheses. The risks associated with the use of bone cement appear to be minimal, and any potential risk can be offset by the increased morbidity and mortality associated with sustaining a periprostheticfractureand the further surgery that is often required for this complication. Whilst they appreciate that the study is retrospective and the patients were not randomised to a prosthesis group, they conclude that for displaced intracapsular femoral neck fractures, a cemented prosthesis is preferable. A prospective randomised trial between the two prostheses is warranted.

Simon S. Jameson [134] did the study over 70,000 hemiarthroplasties for fractured NOF they found that 4-year revision following cementlesshemiarthroplasty was associated with over twice the revision rate of

cemented implants. In addition, patients with a cementless prosthesis had significantly more chest infections in the immediate post-operative period. This supports the national guidelines recommending cement fixation of hemiarthroplasty, and represents a modifiable parameter that can improve outcome in this high-risk group of patients. Observational data has limitations, and the results could be subject to selection bias. They tried to control for this potential bias by adjusting for measured variables and attempting to match patients in both groups using two statistical methods. However, similarities between the methods support the stability of estimates. have developed such that stable implant fixation may now be possible with more complex and costly implants. Within the cementless group they are unable to describe differences between older generations and newer implant designs. However, results from studies examining the newer generations have been encouraging one.

Hakan Cicek [55] took an treatment called Hemiarthroplasty which is widely accepted as the optimum treatment for displaced femoral neck fractures in most elderly patients. Hemiarthroplasty, which allows rapid rehabilitation, is performed as an alternative to osteosynthesis in elderly patients with femoral neck fractures. However, the choice of prosthesis is remain controversial; some authors advocate the cemented prosthesis, whereas others prefer the cementless prosthesis. Internal diseases, cardiovascular diseases in particular, which are observed in advanced age groups, indicate that early mobilization is of utmost importance in terms of morbidity and mortality. Currently, the methods implemented with and without cement play a significant role in problems. observed during hemiarthroplasty operations. Cemented fixation is advantageous for enhancing the initial fixation strength in aged patients with poor bone quality whereas cementless fixation facilitates biological fixation and can avoid cardiovascular toxicity. Some studies have reported positive outcomes in arthroplasty using cementless implants in elderly patients with an improvement of the implant design, material and insertion technique. The cemented technique has been used more frequently for bipolar hemiarthroplasty in this patient group compared to the cementless technique. the outcome of bipolar cementless hemiarthroplasty in the treatment of femoral neck fractures is at least as effective as intervention with cement in the early postoperative period and short term assessments. It also provides clinical advantages in terms of the low re-operation risks and perioperative.

Dinko Vidovic [40] studied that Surgical management of displaced femoral neck fractures in elderly patients remains an important issue and opinion varies as to what should be the most appropriate management. Lack of consensus prevails on the use of the cemented or cementless HA among orthopaedic surgeons. This reflects the contrasting views within the current literature. Bone cement forms a solid bond between stem and endosteum providing favourable biomechanical advantages. It complies with two crucial demands: stability of the interfaces by in situ polymerized interlock; and well defined load distribution through compliant cement mantle. However, there are some concerns on the routine use of the cement in elderly patients with femoral neck fractures including the higher risk of cardiopulmonary complications, longer operative times, the procedure is technically more demanding, and revision surgery could be more challenging.³¹ In our study cemented HA took on average only 11 minutes more in comparison with cementless HA. However, this finding is comparable to those reported in other similar studies in the literature. It may be also argued that cementing is more demanding than 'simple' implantation of the cementless Moore prosthesis, but tight fit of the prosthesis in canal required for primary stability may result in iatrogenic periprosthetic fracture. Adverse events on cardiopulmonary system from hypotension to cardiac arrest associated with use of the cement have also been documented

due to bone marrow and air embolization. Nowadays however due to the modern anesthesiological protocols the incidence of these complications is small.

GX Ni, WW Lu, KY Chiu [54] suggested that the optimal method of fixation for primary total hip replacement, particularly the femoral component. We performed a systematic literature review to explore whether cemented totalhip replacement can achieve better clinical and radiological outcomes. A total of 29 publications were selected using computer-aided and manual searches. A qualitative comparison of results in clinical and radiological changes was then conducted. Most of the literature showed that better short-term clinical and functional outcomes could be obtained from cemented femoral fixation than from uncemented femoral fixation. Results were less clear for the mid-term clinical outcome, though in general, cemented fixation still appeared to show a superior clinical outcome. Radiographic differences are variable and do not seem to correlate with clinical findings. For the short- and mid-term, cemented femoral component is recommended. However, a long-term randomised trial combined with a large cohort study or registry is needed.

Dr. Mohammed Haneef [114] found that the material of prosthesis and the durability of alternate bone material is of critical importance, because it largely determines how load is transferred through the stem. In the geometry and design of the material, the young's modulus of a material is critical design variable. The polymeric biocomposites reasons, why they are becoming most common composites, include their low cost, high strength and simple in manufacturing principles by molding process. But they suffer from poor mechanical properties like higher wear rate, lower hardness and Young's modulus. An attempt has been made to develop hybrid bio polymer matrix composites using high density poly ethylene as the matrix material with Titanium Oxide (TiO₂) particles and Alumina (Al₂O₃) particles as the reinforcement material with varying percentage using extrudal injection moulding machine. The different testing namely, tensile, hardness, flexural strength, density, fractography, corrosion and wear test were conducted on the standard samples prepared. It is found an appreciable improvements in the mechanical and tribological properties of the hybrid polymer matrix composite, which can be used for variety of applications in the human body bone replacement. In this case, their application in orthopaedic as implantable material in the bone surgery has been considered and studied. These composite materials have found wide use in orthopaedic applications, particularly in bone fixation plates, hip joint replacement, bone cement and bone graft.

R. P. Baker [9] compared the medium-term clinical and radiological results of hybrid total hip replacement (THR) with metal-on-metal Birmingham hip resurfacing (BHR) in two groups of 54 young patients matched for age, gender, body mass index and pre-operative levels of activity. The clinical outcome was assessed by the University of California, Los Angeles (UCLA) activity score, the Oxford Hip Score (OHS) and the EuroQol scores. Radiologically, all hips were assessed for migration and osteolysis, the hybrid THRs for polyethylene wear and the BHRs for a pedestal sign. The mean follow-up of the patients with a hybrid THR was ten years and for those with a BHR, nine years. Four patients with a hybrid THR and one with a BHR had died. In each group five were lost to follow-up. The revision rate of the hybrid THRs was 16.7% (9 of 54) and of the BHRs 9.3% (5 of 54) ($p = 0.195$). Radiographs of a further eight hybrid THRs demonstrated wear and osteolysis, and they await revision ($p = 0.008$). Of the unrevised BHRs 90% had radiological changes, of which approximately 50% had progressed over the

previous four years. All hybrid THRs demonstrated linear polyethylene wear with a mean of 1.24 mm (0.06 to 3.03). The BHRs recorded superior OHS ($p = 0.013$), UCLA ($p = 0.008$), and EuroQol visual analogue scores ($p = 0.009$). After nine years, patients with BHRs remained more active and had a lower rate of revision than those with hybrid THRs. Both groups demonstrated progressive radiological changes at medium-term follow-up.

Christopher N. Peck [25] developed the use of cementless total hip arthroplasty (THA) is on the increase. In order to achieve rotational and axial stability larger implants may be required than originally templated for. This could potentially result in a larger leg length inequality. Their objective was to determine whether there is greater inequality in leg length post operatively in cementless THA as compared to cemented implants. 136 consecutive patients undergoing elective THA between June 2007 and May 2008 were included. Post-operative digital radiographs were examined to determine leg length. Twenty seven patients (20%) underwent a cemented procedure and 109 (80%) a cementless procedure. In the cemented group the mean leg length discrepancy was 7.3 mm (range 19 mm short to 21 mm long). In the cementless group the mean measured leg length discrepancy was 6.3 mm (range 18 mm short to 23 mm long). There was no significant difference between the two groups ($P = 0.443$). This study shows that with accurate pre-operative templating, both cemented and cementless procedures produce comparable and acceptable leg length discrepancies.

8. DISLOCATION AND FRACTURE

Arie B. Van [7] studied the main reason for failure leading to non-union is an inadequate osteosynthesis and or poor mechanical conditions, leading to instability. Criteria for optimal reduction and fixation techniques, which can prevent non-union in the majority of cases, are described. The main reason for failure leading to non-union still remains the inadequacy of reduction and fixation which is seen in probably 30% of all cases in the typical non-expert situation. Mechanical factors play an important role in stability of the osteosynthesis and are related to failure, because instead of compression in the fracture-line on weight-bearing, shearing forces occur, leading to a disturbed fracture response weight-bearing, shearing forces occur, leading to a disturbed fracture response. The situation of early failure is more or less comparable to the situation of a delayed diagnosis clue to Late presentation of cases. An open reduction, debridement of the fracture site combined with bone graft and screw-fixation Led to good results in 75% of a rather Large series ($n = 56$) described by Bakshi.

George Georgiou [49] reported of five different cases and reviewed of some literature in this. Dissociation leads almost always to reoperation and possible revision of the prosthesis. To avoid this complication, strict adherence to the surgical technique during the initial procedure and extra precaution during close reduction are recommended, in order to provide enhanced security over component disassembly. All five patients have been treated for a subcapital fracture of the femur with some type of bipolar hemiarthroplasty. They are elderly patients (ages between 75 and 86), although they all report active life prior to the fracture. The duration of the uneventful postoperative period was 2 months for three of the patients and 3—10 years for the other two. Measurements of the chosen parts should be accurate and correct alignment of the arthroplasty to provide increased head coverage during component loading is optimal for minimising any risks of dislocation or wearing on the locking mechanism. The locking

mechanism between the polyethylene cup and the small head must resist a reasonable intra-operative effort to pry it apart. The femoral head component should be firmly impacted onto the tapered neck. It is advised to place the femoral head component after insertion of the non-cemented femoral component as the impaction could result in the loosening of a previously well-fixed femoral head component.

S. Kalra [79] reported in this paper, five out of six patients with an intracapsular hip fracture treated with internal fixation developed non-union or AVN and subsequently required revision to total hip arthroplasty (revision rate of 83.3%). This complication rate occurred despite adequate reduction and fixation in all patients as seen on the post-operative radiographs. This rate of revision after internal fixation is unusually high compared to that in the general population which ranges from 20 to 36%. In those patients with displaced fractures initially treated by hemiarthroplasty one of nine required revision (revision rate of 11%). The failure occurred with an uncemented Austin-Moore type prosthesis that subsided within the pathological bone. This revision rate after primary hemiarthroplasty is comparable to that found in the general population which ranges between 6 and 18%. Further studies will be required to assess the adequacy and risks associated with each form of treatment for patients in ESRF in the long term. In particular, it would be useful to know the long-term rate of revision after primary hip arthroplasty in this group of patients.

Kalpiti K. Patel [72] made the further evidence that total hip replacement in the right hands provides good results for the treatment of displaced intracapsular femoral neck fractures. The Müller straight stem gives acceptable results in a select group of patients. The controversy regarding the best treatment for intracapsular hip fractures in the active older patients remains unsolved. Theoretically, the ideal treatment is anatomic reduction followed by stable internal fixation of such fractures. Whilst most fractures unite satisfactorily, complications include avascular necrosis, non-union, and failure of internal fixation. This has led many authors to consider prosthetic replacement of the femoral head as an alternative. Some authors have recommended total hip replacement. It has been our experience that Müller straight stem hip replacement gives satisfactory results with low complication rates in acute fractured neck of femur patients and has a definite role in properly selected cases. However, the selection of these patients remains a challenge to the judgement of the surgeon. Age and activity status of the patient are important considerations. They selected patients with a healthy active lifestyle and few confounding medical problems. In these patients, associated medical conditions that may preclude a second operation also played a factor. head necrosis and non-union are reported in upto 40% of case.

Philipp Henle [121] suggested the best treatment for Femoral head fractures. Femoral head fractures due to posterior hip fracture dislocation also called Pipkin fractures are relatively rare but often severe injuries. The treatment of femoral head fractures, using the “trochanteric flip” (digastric) osteotomy. Thus inspection of the entire hip joint and accurate fragment reduction under direct visual control are possible. After good initial experiences with this operative procedure they changed our standard treatment regimen to this approach in an attempt to achieve the most accurate anatomic reduction of the femoral head in every affected patient. Between 1998 and 2006 they operated on 12 patients with femoral head fractures associated with posterior hip dislocation, using the new surgical approach. Patients were followed for 2—96 months and outcome was documented with the Merle d’Aubigne and Postel score as well as the Thompson and Epstein score. The posttraumatic formation of heterotopic bone was

documented with the Brooker score. Retrospective analysis of these 12 patients showed good or excellent results in 10 patients (83.3%). The two patients with poor outcome developed an avascular necrosis of the femoral head and underwent total hip arthroplasty. Periarticular heterotopic ossification was seen in five patients. In four patients this caused a significantly reduced range of motion and was therefore considered as a posttraumatic complication. The two patients with the most severe heterotopic bone formation (Brooker III and IV) had initially sustained multiple injuries including brain injury.

Eleftherios Tsiridis [41] found that periprosthetic femoral fractures can be complex and the associated bone loss commonly requires the use of structural allografts. Bone grafting in the form of autograft has well recognized limitations and allograft represents the gold standard of bone augmentation in the majority of the cases. Allograft can be used as morselised in the form of impaction grafting, reconstructing the bone from within out, or in the form of structural allograft. cortical autografts are initially mechanically efficient, although because of their dense structure, revascularisation is slow, and as a consequence they become osteoporotic and mechanically deficient due to osteoclast bone resorption. Autogenous bone graft is effective; however, the supply is limited, donor site morbidity is common, and complications that result from harvesting range from 10% to 25%.

Alexander Siegmeth [3] studied various treatment principles for PFF depend on the location of the fracture in relation to the femoral component, stability of the stem, quality and quantity of the host bone, age and medical comorbidities of the patient as well as surgeon's preference, training and experience. Fractures around the stem with a stable implant bone interface and adequate bone stock (B1) can be treated with component retention and internal fixation. Loose implants with adequate bone stock (B2) need to be revised. Difficulties arise in type B3 fractures. These are characterised by a loose femoral component and inadequate host bone stock. Specialised implants and techniques are necessary. salvage procedures for the treatment of PFF are necessary when a loose femoral component with poor host bone stock is present. Options include revision to a long-stem prosthesis (proximally coated with diaphyseal fixation or fully coated), a proximal femoral replacement, and bone-reconstituting procedures such as cortical strut grafting in combination with a long-stem component and a proximal femoral allograft. The former are preferred in elderly and low-demand patients. But in the majority of patients bone reconstituting procedures are preferred.

Hsin-Pai Lee [60] studied various procedures are performed under topical anaesthesia. However, surgical repair of hip fracture is considered a grade 3 surgical risk. Most of the outcomes, laboratory data were stratified into normal and abnormal with the use of specific cutoff values determined by our institutional clinical laboratory. The odds ratio (OR), 95% confidence interval (CI), and P values were reported. In the second step, they used univariate analysis to determine the variables that had significant association with postoperative adverse outcome ($P < 0.05$) and entered them in a stepwise multimodel. they used univariate and multivariate analysis to investigate the relationship between preoperative comorbidities and abnormal laboratory findings. All the analyses were carried out using SPSS.

I.D. Gelalis [91] investigated that Acetabular periprosthetic fractures due to different reasons and managed by various types of treatments are described in the literature. Those fractures can occur during the insertion of the acetabular component, due to high impaction forces. Sharkey et al. reported a series of

13 patients within traoperative, acetabular fracture during insertion of various cementless acetabular components. Contributing factors for this complication include insertion of an oversized component, Paget's disease and osteopenia.. Those cases were thought to be a result from infection or periprostheticosteolysis. Our primary objective was to achieve a stable construct rather than a truly anatomical restoration. The above, in combination with the use of bone allograft, would also allow formation of sufficient bone stock for further revision arthroplasties, taking under consideration the relatively young age of the patient. This strategy helped to limit the need for an extensile exposure and led us to the non-use of reconstruction plates. The same posterior approach used at the initial surgery allowed for both total hip arthroplasty and fixation of both columns of the acetabulum, mainly through the acetabular cup. The cause of this fracture pattern is open to speculation. The mechanism of injury was dash-board striking of the knee of the patient in an automobile head-on collision. Given the fact that the acetabular component was found loose and with little bone in growth on the shell during surgery, we assume that this acetabular cup-head double movement magnified the forces exercised upon the acetabulum.

Neil M. Orpen [101] took the fractures of the neck of femur can usually be attributed to technical aspects of the surgical technique but even in experienced hands may occur in 0.5–2.1% of cases. Gender, body weight and proximal femoral bone quality are also factors associated with early periprosthetic fracture and should be considered in the preoperative workup when considering a patient's suitability to undergo a surface replacement. Typically fractures occur in the early postoperative period and occur in the subcapital region. Often these can be treated nonoperatively if undisplaced or with revision to total hip replacement if the fracture is significantly displaced. The fracture was clinically and radiologically united at 3 months and at 6 months the patient was asymptomatic No further problems had arisen at 1-year post-fixation. We know that the loading of the proximal femur after a resurfacing arthroplasty is non-physiological⁴ and it may be this abnormal loading, which leads to stress risers and potential fractures in the intertrochanteric region. Whatever the cause, the mechanism leading to fracture appears to be distinctly different to that which results in a subcapital fracture and the treatment is complicated by the prosthesis stem which lies in the mid portion of the neck in one of our patients the fracture was the result of a high energy fall and the level of activity likely to result in these types of injuries may be more likely in this younger group of arthroplasty patients undergoing surface replacements. The treatment of this injury pattern following a resurfacing arthroplasty of the hip has only been described in one similar case where a blade plate was used to address a two-part fracture below a resurfacing.⁶ As surface replacements are used more commonly, they expect that these atypical injury patterns will start to emerge. They have found this device a good option in the management of this unusual fracture pattern and believe internal fixation should be considered as an alternative to revision of the surface replacement in this situation. It is essential to report these unusual fracture patterns in new devices such as the resurfacing garthroplasty so that they can build up documented solutions on how to deal with uncommon associated injuries.

G. Riouallon [118] diagnosed about vascular injuries during the course of total hip arthroplasty (THA) implantations are rare. They must be constantly feared as they sometimes put at risk the vital and functional prognosis of the operated limb. We report the case of a common femoral artery injury diagnosed by arteriography within two days of THA replacement in the presence of atypical symptoms. The vascular damage was caused by an arterial lesion resulting from positioning a retractor on the anterior

wall of the acetabulum. A literature review on the topic of vascular complications arising after THA made us aware of multiple possible mechanisms and clinical presentations relating to such complications while identifying specific risk factors in THA replacement cases. Acetabular revision constitutes a major risk situation. Most of these vascular complications may be better prevented or more efficiently treated by thorough preoperative assessment and careful postoperative monitoring. This instance of diagnosis obtained through close postoperative follow-up suggests to confirm the need for actively searching a vascular complication in presence of any unusual distal vascular compromise symptom following hip prosthesis surgery. This is even more true when there are other risk factors that should have been preoperatively recognised. Finally, the analysis of each individual situation should determine if preoperative arteriovenous opacification is necessary on one hand, eventually resulting in appropriate surgical conduct on the other hand: deliberate use or not of a retroperitoneal approach for iliac vessels primary control prior to the orthopaedic act.

LIU Xian-zhe [86] had made a Clinical observation of particulate cancellous bone impaction grafting in combination with total hip arthroplasty for acetabular reconstruction. For this they investigated the effect of particulate cancellous bone impaction grafting in combination with total hip arthroplasty (THA) for acetabular reconstruction in patients with posttraumatic arthritis and bone loss after acetabular fractures. Particulate cancellous bone impaction grafting in combination with THA as a biological solution is an attractive procedure for acetabular reconstruction in patients with posttraumatic arthritis and bone loss after acetabular fracture, which can not only restore acetabular bone stock but also repair normal hip anatomy and its function.

LIU Xian-zhe [87] conducted the treatment of elderly patients with comminuted intertrochanteric fracture accompanied by femoral head necrosis. The main aim to assess the curative effect and investigate the indications of total hip arthroplasty for treatment of comminuted intertrochanteric fractures. At the last follow-up, the patients gained 86 points (70-100 points) according to the Harris score. The effects of the 8 cases were good. The Harris score of all patients improved after treatment. Only two hemiplegia patients needed sticks to walk. The others could walk without hip pain. No radiographic evidence of acetabular wear and prosthesis dislocation or other major complications happened during the follow-up. Prosthetic replacements can well treat unstable intertrochanteric fracture if operative indication is correctly selected. It is suitable for elderly patients and the operation should be performed by experienced surgeons.

A. Ahmed [2] investigated that Fractured neck of femur is one of the commonest fractures sustained in the elderly population. An antero-posterior (AP) view of the pelvis and lateral view of the affected hip are routinely taken. We present an unusual case of an intra-operative complication while inserting an Austin Moore Hemiarthroplasty, due to inadequate radiographs of the femur. Displaced fractured neck of femur is treated with hemiarthroplasty in the elderly population. Intra-operative periprosthetic femoral fractures are rare but present a challenge for the surgeon. The calcar may fracture during surgery, the stem may penetrate the femoral shaft, or distal femoral fracture can occur during manipulation and preparation of the femur. Proximal fractures are usually easily seen during surgery, but fractures at the tip of the stem

that occur during surgery may be missed. These fractures may delay post-operative mobilisation and increase morbidity and mortality. They also increase the hospital stay and cost. In our patient, it was difficult to obtain a proper medical history from the patient at the time of admission because of his Alzheimer's dementia. Where a proper history is not available, in a patient with a fractured neck of femur, we suggest that the radiograph should include at least the upper half of the femur in addition to the hip joint. Although it could be argued that intra-operative screening of the femur at the time when some difficulty is encountered could have avoided this complication, a proper pre-operative diagnosis would also have alerted the surgeon to the need for more care when performing the operation and more importantly would have identified the need for a more experienced surgeon.

S.Hindocha[59] suggested that Atraumatic fracture neck of femur in Marfan's syndrome the skeletal manifestations of MS are well described within the literature. One complication of the disease which appears to be under controversial debate is the relation of bone mineral density and the development of fractures. The increased risk of reduced bone mineral density in MS would appear to be a risk factor for atraumatic fractures. Although the significance of reduced bone mineral density and risk of fractures has been disputed it has been shown that bone mineral density within the trochanteric area is reduced in the Marfanoid patient. Since this connective tissue disease is well known to affect the vascular system, Marfanoid patients presenting with fracture neck of femur will be at increased risk of developing AVN. As far as we aware this relationship has not been reported and would benefit from further review and opinion. The majority of vascular abnormalities described are those of heart valvular dysfunction, dilated cardiomyopathy, aortic aneurysm and dissection.⁶ Vascular abnormalities relating to the skeletal system such as AVN to the head of the femur have not been clearly recognised.

Subramanyam Naidu Maripuri [140] revealed that occult femoral neck fractures necessitate repeat radiographs or MRI scans to confirm the diagnosis. The treatment of intracapsular fractures differs from extracapsular fractures. Therefore, differentiation between these two is mandatory preoperatively. Failure to diagnose the fracture in some cases may be due to the position of the limb at the time of obtaining radiographs. In general, the position of a fractured or painful hip is external rotation. A prominent lesser trochanter seen on plain radiograph confirms that the hip was externally rotated when X-rayed. Lesser trochanter becomes less prominent in an internal rotation view. The 158 internal rotation view is the true AP view of neck of femur as it removes the beam parallax and positions the long axis of the neck perpendicular to radiographic beam. It facilitates identification of occult fractures,¹ which may not be evident on other views and therefore reduces the need for MRI scans. It also provides information about the length of calcar, differentiates basicervical fractures from transcervical fractures. It helps in planning of surgery and selection of implant or prosthesis. Although, concerns about causing pain while internally rotating the fractured leg exist, with the routine analgesic regimen used in fracture neck of femur (opioids or femoral nerve block), patients do tolerate internal rotation very well. Bandaging legs together helps in keeping the leg internally rotated while obtaining the radiographs described helps in better understanding of fracture pattern and preoperative planning. We recommend internal rotation view in occult hip fractures before proceeding to MRI scan.

I.G. Murphy [98] discussed about the sliding hip screw is associated with a number of complications, including varus deformities or internal rotation, cutting out, penetration of the guide wire and

disengagement of the components. This can occur between the plate and the shaft of the femur, or as in our case with the sliding screw and plate. Case reports of this complication are rare. Rao and Pringle report the case of retroperitoneal migration of the sliding screw. At operation, they were unable to access the screw and it was left in-situ. Injury to deep pelvic vessels after hip surgery is well described and is usually iatrogenic. Moreyra et al describe a fatal case of laceration of deep pelvic vessels due to penetration of the sliding screw. Brodell et al describe a case of free intraperitoneal protrusion of the lag screw. possible mechanism for proximal migration, that unequal loading may result in the screw being unable to slide in the barrel thus resulting in proximal loading on weight bearing. The authors conclude that this is more likely in unstable (e.g. four-part) intertrochanteric fractures. In our case, we feel the likely cause was fracture of the neck of femur with a sliding hip screw already in-situ. Sliding of the screw was unable to compensate and the screw was therefore, forced into the acetabulum and subsequently, the pelvis with attempted weight bearing.

Praveen Mereddy [113] reported an intertrochanteric femoral fracture distal to the hip resurfacing implant treated successfully with an angled blade-plate. Revision to a stemmed modular component is more frequently performed for a displaced sub-capital/trans-cervical peri-prosthetic fracture neck of femur following metal-on-metal resurfacing. It is important to individualise treatment depending on the fracture location and configuration, patient characteristics and surgeon's experience. In the current case, with the fracture being basi-cervical the possibility of better fracture union and survival. rate of the femoral head was considered. The option of minimally invasive percutaneous fixation with little risk in comparison to a more complex revision lead the senior author to attempt internal fixation rather than a revision. In a national review of 50 femoral neck fractures following Birmingham hip resurfacing, Shimmin and Back report a failed attempt to fix a sub-capital femoral neck fracture intra-operatively with a cannulated screw by one of the participating surgeons in their study.

M. Grimaldi [53] had done a femoral neck fractures Treatment by bilateral total hip arthroplasty. Twenty cases of bilateral femur neck fractures after convulsive seizure have been reported in the literature since 1970 . Most often, they are secondary seizures (cerebral metastases or eclampsia, which are metabolic or iatrogenic, due to electroconvulsive therapy) but more infrequently primary epileptic seizures. The mechanism of these lesions was discussed by Pearson and Hargadon in 1962 , then by Remec and Evarts in 1983 . According to these authors, violent contraction of the periarticular muscles, and particularly the pelvic-trochanteric muscles during the seizure, is the principle cause of these fractures. Cases of concomitant, associated fractures, especially at the level of the proximal humerus and acetabulum , can be found in the literature. The high risk of aseptic osteonecrosis of the femoral heads compelled us to perform bilateral hip arthroplasty in a single operation, despite the elevated threat of prosthetic dislocation. The influence of THA dislocations on femoral neck fractures is, in fact, more significant than that observed in arthroplasties for osteoarthritis. The risk is increased in the event of iterative, repeated comitial seizure. The young age of our patient (49 years) and his active lifestyle led us to choose a ceramic-on-ceramic bearing type that has a longer lifespan without osteolysis or wear than a more stable dual mobility cup that has a higher risk of aseptic unsealing in young patients . The choice of a cementless cup and stem follows the same principle of longevity. In this case, diameter size of 32mm allowed better behavior with respect to prosthetic dislocation, compared to a smaller diameter. vitamin D and calcium supplementation as well as control of bone mineral density in patients taking a particularly

long course of antiepileptic treatment, especially if they present other bone pathologies. This physiological bone aspect is an additional unfavorable argument against the osteosynthesis of femur neck fractures with major displacement in treated epileptic patients. Bone histology in our patient was normal, although bone densitometry (DEXA) was not investigated. The major vascular risk of aseptic femoral head necrosis is a determining factor in the choice of total arthroplasty for femoral neck fractures, even if the patient is epileptic and young.

Fabiano Bolpato Louresa [45],[46] aims to estimate the cost per quality-adjusted life-year (QALY) focusing on the length of time between trauma and surgery. The aim of this study was to analyze the relationship between cost, from the perspective of the Brazilian National Health System (SUS), and the effectiveness of surgical treatment for hip fractures among elderly people in Brazil, focusing on the time that elapses between injury and surgery. After controlling for the confounding variables of age, gender, type of fracture, type of treatment and ASA anesthesiarisk, the cost-usefulness ratio of the early-surgery strategy (<4 days) was shown to be superior to the late-surgery strategy (>4 days). The economic analysis conducted here provides backing for determining that early surgery should be the ideal for guidelines within Brazilian realities and for allocation of resources to seek this objective.

Justine M Naylor [70] observed improvements in the SF-36 domains were such that the scores approached population norms (ABS 1995) (more so for nonobese patients and those without severe other joint disease), and this observation accords with other local (Bachmeier et al 2001, March et al 1999) and international studies (Fortin et al 1999, Fortin et al 2002, Stickles et al 2001) reporting outcomes one to two years post joint replacement. The large improvements observed in WOMAC scores are also typical (Bachmeier et al 2001, Kennedy et al 2006, Stickles et al 2001), as are the improvements in operated joint pain (Roder et al 2003), and the finding that, for many outcomes, most improvements occurred within the first six months post-surgery. The stratification of patients according to the presence of severe other joint disease or obesity was useful as it revealed that the presence of these impairments was associated with poorer rates of recovery and/or absolute recovery for several outcomes at one year. Poorer WOMAC scores up to seven years. This conclusion is corroborated by the current study since, independent of obesity, patients perceived major global improvements in their joint behaviour. Though obesity or severe other joint disease did not preclude improvement in walk speed, stratification of the cohort revealed that patients with such co-morbidities remained slower than age-matched norms.

Leah C. Elson [82] studied that Acetabular cup positioning is a critical factor in determining adverse clinical outcomes in THA. This evaluation was performed to determine if morbid obesity (BMI ≥ 35 kg/m²) is a contributing risk factor to cup malpositioning. Two groups of patients were obtained from a local arthroplasty registry and match-controlled for gender, age, and diagnosis (n = 211 morbidly obese; n = 211 normal). Intraoperative data and postoperative AP pelvis and cross-table lateral radiographs were obtained for each patient. The Martell Hip Analysis Suite was used to calculate cup positioning (successful positioning defined as 30°–45° of abduction, and 5°–25° of anteversion), as well as varus–valgus alignment of the femoral stem. There was a significant correlation between morbid obesity with respect to underanteversion; using multivariate analysis, there was a trend toward a combined underanteversion/overabduction of the acetabular cup. Of all variables considered, high BMI was the most significant risk factor leading to malpositioning.

Kigera J W M1, Okello [77] revealed the dislocations of the hip associated with fractures of the neck of femur are rare entities. We report a case of a 23 year old man involved in a road traffic crash and sustained a posterior hip dislocation of the right hip with an associated fracture of the neck of femur. This is a rare case but may occur in high energy injuries. He was managed by bipolar hemiarthroplasty as opposed to total hip athroplasty due to financial constrains. This case highlights the challenge of treatment of posterior hip dislocation in the setting of associated femoral neck fracture, late presentation and resource constraint. This case should alert the clinician to this rare injury and the possible modes of management available to the surgeon including the possibility of athroplasty for late presenting cases despite the intact joint surfaces. In our case the head of femur was found trapped in the gluteal muscles and it was felt that open reduction and internal fixation would not have been appropriate. Management with hemiarthroplasty will undoubtedly have long term issues that will need to be addressed including the possibility of revision in the near future.

Ole-Christian L. Brun [104] studied the incidence of greater trochanteric fractures at our department following THR. In all we examined 911 patients retrospectively and found the occurrence of a greater trochanteric fracture to be 3%. Patients with fractures had significantly poorer outcome on Oxford Hip score, Pain VAS, Satisfaction VAS and EQ-5D compared to THR without fractures. Greater trochanteric fracture following THR is one of the most common complications following THR. It has previously been thought to have little impact on the overall outcome following THR, but our study suggests otherwise. Further investigation should focus on finding the best treatment option for type 3 fractures and to further investigate type 2 fractures. It seems clear that a fracture caused by cutting off the top part of the trochanter during the femoral neck osteotomy (type 1) has less or no impact on the outcome of THR, possibly because this fracture (and type 2 fractures) do not violate the gluteus medius muscle significantly.

Dr.A.K.Venkatachalam [147] took an Acetabular fractures are often sustained in four wheeler accidents. Most patients are young. The ideal treatment is internal fixation in displaced fractures. In neglected fractures or following improper fixation, avascular necrosis and secondary osteoarthritis result1. In such cases total hip replacement is required. These case reports illustrate total and short stem hip replacement for neglected acetabular fracture. Acetabular fractures are a leading cause of secondary osteoarthritis requiring total hip replacement. Usually these injuries occur in young people. Ideally, THR will be uncomplicated; however, associated problems may compromise the treatment and result2-4. Retained implants, bone defects, nonunion, innominate bone deformity, impaired musculature, heterotopic ossification, and infection are important to consider when planning reconstruction and hip replacement. A posterior approach was chosen to perform the hip replacement in both cases. Traditionally total hip replacement with an uncemented hip replacement has been successful. One of these two cases received a short stem hip replacement with the Proxima hip5. The Proxima hip has the advantages of preserving bone stock and permitting revision to a total hip replacement in future.

Jeffrey N. Katz [66] provided the background on the epidemiology and management of osteoarthritis of the hip, including total hip replacement. We describe the utilization rates and outcomes of THR, with

emphasis on the key outcome for this proposal -- failure of the prosthesis, leading to a revision procedure. We include data on the association between hospital and surgeon volume of THR and outcomes, including failure. The rates, mechanisms and management of THR failure are reviewed. We close by discussing the national total joint registries developed in Scandinavian countries to monitor failure of THR, and preliminary efforts in this country to mount such registries. The authors are embarking on a federally funded study of the epidemiology and outcomes of revision total hip replacement in the US Medicare population. This paper reviews background information on the epidemiology and outcomes of revision total hip replacement. Our goal is to identify critical gaps in the published literature on rates and predictors of revision total hip replacement among patients who have had a primary THR.

Anastasios K. Lilikakis [4] investigated the low-molecular-weight heparins are a group of agents widely used in the prevention of deep-vein thrombosis and pulmonary embolism in orthopaedic patients, especially those undergoing total joint replacement of the lower extremity. They have been in clinical use for almost twenty years and have proved to be at least as effective as other means of thrombosis prevention¹. The American College of Chest Physicians has recommended them for routine use in total hip replacement for the past ten years, as an alternative to warfarin and adjusted-dose unfractionated heparin^{2,3}. Their main advantages are that they can be used without laboratory monitoring and they have a favorable therapeutic index (less risk of bleeding compared with unfractionated heparin for a given antithrombotic effect)⁴. Bleeding and thrombocytopenia are, however, documented complications of the use of low-molecular-weight heparin⁵⁻⁹, but, to our knowledge, cerebral hemorrhages secondary to thrombocytopenia have not been reported in association with orthopaedic procedures. We report the cases of two patients who had thrombocytopenia and cerebral complications after routine treatment with low-molecular-weight heparin for thromboembolic prevention following total hip replacement. Our patients or their families were informed and consented that data concerning their cases would be submitted for publication.

Fernando Judas [145] made study on Dislocations of total hip prostheses cause pain and patient dissatisfaction. Recurrent dislocations are difficult to treat mainly when the acetabular metal shell is well-fixed. The purpose of this article was to describe the surgical technique used for the treatment of a bilateral recurrent posterior dislocation after a cementless total hip prosthesis, caused by excessive inclination of acetabular components, in a 72-year-old patient. On both sides, acetabular metal shell, porous-coated, was well-fixed. Revision of the entire acetabular component could be an appropriate therapeutic option because it was malpositioned. Nevertheless, a conservative operation was performed. The metal shell was left *in situ* and the preexisting polyethylene liner was removed and replaced by a new undersized cross-linked polyethylene liner, then, cemented into the shell and properly oriented. An acetabular cemented augmentation reinforced by 3 cortical screws was associated with the reconstruction. This report suggests that cementation of new liner into a malpositioned well-fixed metal shell associated with an acetabular cemented augmentation is a simple and safe technique for the management of recurrent hip dislocation, for elderly patients in which it is advisable to avoid a major revision hip surgery by medical comorbidities. Nonetheless, further studies with medium-and long-term follow-up are needed to validate this technique.

9. MINIMALLY INVASIVE IN TOTAL HIP REPLACEMENT.

H. Wolf [146] investigated the extensile approaches (e.g. extended iliofemoral, triradiate, Maryland modifications) have been recommended to improve direct visualisation and reduction of more complex acetabular fracture patterns. These extensile approaches have been reported to result in increased morbidity due to longer operative time, infection, greater blood loss, abductor weakness and heterotopic ossification. On the other hand, some new modifications of the ilioinguinal approach were designed not to replace the classic approach but to expand its utility. gives an overview of the recent modifications of the ilioinguinal approach. The modified ilioinguinal approach can be used to treat all fractures currently treated according to the classic approach as described by Letournel.⁷ This newer approach is useful for fractures with medial protrusion of the femoral head (medial displacement of the quadrilateral surface). Anterior pelvic ring injuries (symphyseal disruption) and contralateral pubic ramus fractures are also easily accessible. The rate of complications in our patients equalled reported rates in recent studies. The modified ilioinguinal approach can reduce the risk of developing some of the complications associated with the classic ilioinguinal approach. Opening of the inguinal canal is not necessary; thus, the integrity of the inguinal floor is not compromised, and the risk of iatrogenic hernia is diminished. Additionally, there is no dissection around the femoral blood or lymphatic vessels.

Philipp Kobbe [109] studied about Less invasive stabilisation system (LISS) for the treatment of periprosthetic femoral fractures. Periprosthetic fractures after total hip replacement represent serious complications and are difficult to treat. In this study we analysed the complications and mid-term functional outcome of periprosthetic fractures stabilised with the internal fixator LISS. In these cases the LISS proved to be an implant associated with low complication rates and good functional outcome. The assessment of a successful periprosthetic fracture treatment is difficult. On the one hand the patient population reflects an age group with impaired mobility even in healthy subjects and on the other hand pre-injury functional scores are usually not available. Because there is no scoring system for the outcome of periprosthetic fractures, we used the Harris Hip score and the Karnofsky activity index to describe the functional outcome. They conclude that within its indications the LISS is a suitable implant with low complication rates and good mid-term functional outcome for the treatment of periprosthetic fractures.

P. Pilot [12] has been suggested that minimally invasive surgery (MIS) in total hip replacement (THR) is less traumatic than standard techniques. This study was designed to address the question of whether an anterior MIS approach generates less inflammation and muscle damage than the standard posterolateral (PL) approach. Inflammation parameters such as interleukin-6 (IL-6), muscle damage parameters like heart type fatty acid binding protein (H-FABP), and haemoglobin (Hb) levels were determined pre-operatively and at five consecutive points post-operatively in 10 patients operated through a MIS anterior approach and in 10 patients operated through a PL approach. The mean IL-6 concentration increased from 3 pg/ml in both groups pre-operatively to 78.5 pg/ml (PL group) vs 74.8 pg/ml (MIS group) at 6 hours post-operatively and reached a maximum of 100 pg/ml (PL group) vs 90.5 pg/ml (MIS group) after 24 hours. Up to this time point, there was a decrease in both groups. The post-operative mean H-FABP concentration increased to 10.7 mg/l in the PL group vs 15.8 mg/l in the MIS group. It formed a plateau and decreased after 24 hours postoperatively. The Hb levels were 14.5 g/dl before surgery and decreased to 10.7 g/dl (PL group) and 10.0 g/dl (MIS group) at 72 hours post-operatively. No significant differences

were found between the two approaches either in inflammation and muscle damage or blood loss. Although the absence of a learning curve may explain the lack of a difference between both techniques, we speculate that the term MIS is at least doubtful in terms of being less traumatic.

DayanandManjunath [37] studied the average age of patients was 56 years, most common diagnosis was avascular necrosis of femoral head and 90% of patients were less than 30 BMI which indicates mini incision approach is preferable in thinner patients. Average duration of surgery was 75 min and average amount of blood loss was 600ml and average blood transfusion was 350ml which is less than usual attributed to small incision. Average preoperative Harris Hip score was 35 (range 24-45) and average postoperative Harris hip score was 89 (range 79-91). Average cup abduction angle was 440 (range 35-550), only one outlier (<350) was seen may be due to poor visualisation. Only one femoral stem was placed in varus, average postoperative limb length.

Kevin Heaton,[76] made a follow-up period for these 5 patients ranges from 7 to 36 month, and each patient is satisfied with the results. None of the patients have any limitations even with flexed hip activities. Each had significant relief of the preoperative groin pain within 6 to 8 weeks after the operation. Balancing of the soft tissues around the hip during THA has been described previously [6,7]. Proper soft tissue tension remains as important as correct positioning of the components. Even with proper replacement of the acetabulum and appropriate soft tissue balancing, patients occasionally may develop iliopsoas tendinitis. Conservative treatments should be attempted initially, including anti-inflammatory medication, physical therapy, and injections with corticosteroids and local anesthetics. If nonoperative treatment is not successful, patients benefit from surgical release. This operation is simple and can be performed through a small segment of the previous surgical incision. In our experience, these patients obtain substantial pain relief with no perceived impairment of strength or function. The treatment of iliopsoas tendon release is a much simpler operation for the surgeon and the patient than revision of the cup and should be tried initially. If the cup is determined to be in retroversion or is laterally placed on the radiograph, which means the anterior wall can be prominent above the bony wall, release of the iliopsoas tendon can be curative. If the patient is dislocating, the cup should be revised rather than the tendon released.

Anne McMurray [6] investigated the recovery from total hip replacement over a three-year period on the basis of patient perceptions of health-related quality of life, demographic (age, gender, family support) and clinical characteristics (co-morbidities, hospital admissions), use of and satisfaction with health services, unmet health needs and social re-engagement. Recovery after hip replacement surgery is dramatic, especially in alleviation of pain, but for older patients, there is a subsequent decline in general health concomitant with others in this demographic group. Differences in men's and women's patterns of recovery suggests differential planning to provide more realistic expectations for recovery and aftercare.

10. DISEASES RELATED TO TOTAL HIP REPLACEMENT (THR).

Clifford W. Colwell [29] found that the Thromboembolic disease is a common complication of total hip arthroplasty. The purpose of this study was to compare a new mobile compression device with low-molecular-weight heparin with regard to their safety and effectiveness for the prevention of venous

thromboembolic disease. Four hundred and ten patients (414 hips) were randomized; 392 of these patients (395 of the hips) were evaluable with regard to the safety of the intervention and 386 patients (389 hips) were evaluable with regard to its efficacy. Demographics were similar clinically between the groups. The rate of major bleeding events was 0% in the compression group and 6% in the low-molecular-weight heparin group. The rates of distal and proximal deep venous thrombosis were 3% and 2%, respectively, in the compression group compared with 3% and 1% in the heparin group. The rates of pulmonary embolism were 1% in the compression group and 1% in the heparin group, and there were no fatal pulmonary emboli. Within the twelve-week follow-up period, two events (one deep venous thrombosis and one pulmonary embolus) occurred in one patient in the compression group following negative findings on duplex ultrasonography on the twelfth postoperative day. There was no difference between the groups with regard to the prevalence of venous thromboembolism. When compared with low-molecular-weight heparin, use of the mobile compression device for prophylaxis against venous thromboembolic events following total hip arthroplasty resulted in a significant decrease in major bleeding events.

Paul T. Williams [106] conducted the activities like Running and other strenuous sports are purported to increase osteoarthritis (OA) risk, more so than walking and less-strenuous activities. Analyses were therefore performed to test whether running, walking, and other exercise affect OA and hip replacement risk and to assess the role of body mass index (BMI) in mediating these relationships. Methods: In this article, we studied the proportional hazards analyses of patients' report of having physician-diagnosed OA and hip replacement versus exercise energy expenditure (METs). Results: Of the 74,752 runners, 2004 reported OA and 259 reported hip replacements during the 7.1-yr follow-up; whereas of the 14,625 walkers, 696 reported OA and 114 reported hip replacements during the 5.7-yr follow-up. Compared with running 1.8 METs, the risks for OA and hip replacement decreased as follows: 1) 18.1% ($P = 0.01$) and 35.1% ($P = 0.03$) for the 1.8- and 3.6-METs run, respectively; 2) 16.1% ($P = 0.03$) and 50.4% ($P = 0.002$) for the 3.6- and 5.4-METs run, respectively; and 3) 15.6% ($P = 0.02$) and 38.5% ($P = 0.01$) for the 5.4-METs run, suggesting that the risk reduction mostly occurred by 1.8 METs. Baseline BMI was strongly associated with both OA (5.0% increase per kilogram per square meter, $P = 2 \times 10^{-8}$) and hip replacement risks (9.8% increase per kilogram per square meter, $P = 4.8 \times 10^{-5}$), and adjustment for BMI substantially diminished the risk reduction from running 1.8 METs for OA (from 16.5%, $P = 0.01$, to 8.6%, $P = 0.21$) and hip replacement (from 40.4%, $P = 0.005$, to 28.5%, $P = 0.07$). The reductions in OA and hip replacement risk by exceeding 1.8 METs did not differ significantly between runners and walkers. Other (nonrunning) exercise increased the risk of OA by 2.4% ($P = 0.009$) and hip replacement by 5.0% per METs ($P = 0.02$), independent of BMI. Conclusions: Running significantly reduced OA and hip replacement risk due to, in part, running's association with lower BMI, whereas other exercise increased OA and hip replacement risk.

Nancy E. Lane [100] examined that the Hip pain develops gradually and is initially associated primarily with weight-bearing activity, as described by the patient in the vignette, is characteristic of osteoarthritis. A physical examination should be performed to rule out other causes of hip pain, and radiography should be performed to confirm the diagnosis. I would initially recommend treatment with acetaminophen (up to 4 g daily) in lieu of ibuprofen. If his hip pain and function do not improve with this treatment, I would

recommend the initiation of treatment with an NSAID at the lowest effective dose. Given the patient's age, I would add a proton-pump inhibitor to reduce the risk of gastrointestinal side effects. If the pain is not relieved with these medications and awakens him at night, I would consider the use of a narcotic such as codeine or tramadol. The patient should be referred to an arthritis education class in his community and to an exercise program of water aerobics or to a physical therapist at a frequency of twice a week for at least 2 months to improve muscle strength in his legs and the range of hip motion. A physical therapist should also evaluate him for the presence of an inequality in leg length and provide him with a shoe lift if necessary. Although data from randomized trials are lacking, I would encourage weight reduction if the patient is overweight and would suggest that he use a cane while walking, since it might improve his sense of balance and confidence in performing his daily activities.

Lincolshire and goole [85] suggested that they will continue to be some variation even between the specialists, about what activities you can and cannot do following your hip replacement. However, it is generally agreed that you should avoid repetitive high impact activity and that you may never be able to do a full, deep squat again. However, the most important thing to remind yourself of is that you have had this operation to decrease your pain and improve the quality of your life. It is important that you make the most of this improved quality of life, with the understanding that a joint replacement lasts about 15years before it may start to fail and need revising.

Dan Steinitz [156] examined and assessed the risk of postoperative infection associated with blood transfusion in patients who undergo primary total hip arthroplasty. A retrospective cohort study. Victoria General Hospital, Halifax, (a tertiary-care centre). All patients who underwent primary total hip replacement between 1990 and 1995 ($N = 1206$). Hip replacement with or without perioperative blood transfusion. The rate of postoperative infection, the number of blood transfusions, patient age and sex, duration of surgery and the surgeon who performed the procedure. Victoria General Hospital medical records, the transfusion services record and the Dalhousie University Hip Study databases were integrated and analyzed using a standard statistical package. The incidence of infection postoperative was 9.9% overall, 8.4% in patients receiving no transfusion, and 14% in those receiving homologous transfusion ($p = 0.035$). There were no infections in the 11 patients who received an autologous blood transfusion. Significant predictors of postoperative infection were sex, age and duration of surgery; these were not confounding variables (χ^2 multivariate analysis). Neither the operating surgeon nor the blood product transfused affected the infection rate. Conclusions: These findings suggest an increased risk of postoperative infection in patients who undergo primary hip replacement and receive homologous blood transfusions perioperatively.

Daniel Kelmanovich [35] approached, an 8-cm skin incision, located 40% proximal and 60% distal to the tip of the greater trochanter, is made. Sharp dissection proceeds to the fascia latae, which is incised in line with the skin incision. The fibers of the gluteus medius are identified, and the muscle is split one-third from its anterior edge down to the high point on the lateral aspect of the trochanter. The gluteus minimus and capsule are incised longitudinally and dissected off the anterior femur. Dissection proceeds distally to the vastus origin and no further. A blunt Hohmann retractor is used to dissect the capsule posteriorly and anteromedially off the femoral neck. Dislocation can be accomplished at this point, and the THA

proceeds as usual with the standard retractors. Care should be taken to protect the proximal skin edge, particularly when the femur is being broached. Short-term follow-up data indicated no difference in complications rates between mini and standard-incision THA.

Jagwant Singh [64] evaluated a single dose of intravenous TA (10 mg per kg body weight) given 10 minutes prior to THA is a cost-effective and safe means of minimising blood loss and reduction in haemoglobin concentrations as well as the need for allogenic blood transfusion, without increasing the risk of thromboembolic events. The mean intra-operative blood loss (489 ± 281 vs. 339 ± 184 ml, $p=0.048$) and the decrease in haemoglobin level (38 ± 12 vs. 29 ± 10 g/l, $p=0.014$) were significantly higher in the control than the treatment group (Table). Two patients among the controls received a transfusion, compared to none in the TA group ($p=0.49$, Fisher's exact test). The 2 patients who needed blood transfusion had blood losses of 600 and 690 ml, compared to a mean of 489 ml in the whole group. No patient in either group developed deep vein thrombosis or pulmonary embolism up to 3 months.

CONCLUSION

In this paper, a review of total hip replacement and hip prosthesis has been done for more than a couple of decades since 1993 to till date. It will be useful to the researchers who are working on hip prosthesis design and fabrication as well as the failure analysis of hip with different approaches.

REFERENCES

1. Abadie P, 2009, Cemented total Hip stem design influence on adaptive cortical thickness and femoral morphology, Orthopaedics Department, 96, 104—110.
2. Ahmed A, 2006, "Does fracture neck of femur need full-length radiograph of femur", West Middlesex University Hospital, 37, 247—248.
3. Alexander Siegmeth, 2007, "Salvage procedures and implant selection for periprosthetic femoral fractures", Division of Lower Limb Reconstruction and Oncology, 38, 698—703.
4. Anastasios K. Lilikakis, 2006 Low-Molecular-Weight Heparin Treatment in Patients Undergoing Thrombocytopenia and Intra-cerebral Complications Associated with Total Hip Replacement. A Report of Two Cases, J. Bone Joint Surg. Am. 88:634-638.
5. Andrew P. Foster, "Periprosthetic femoral fractures — a comparison between cemented and uncemented hemiarthroplasties", Department of Trauma and Orthopaedics, 36, 424—429.
6. Anne McMurray, 2005, Mapping Recovery After Total Hip Replacement Surge : Health-Related Quality of Life After Three Years, Volume 22 Number 4
7. Arie B. van Must, 2007, "Femoral neck non-unions: How do I do it?", University Medical Centre - 38S, S51-S54.
8. Azrul Hizam Shapui, 2013, "Implant Size Detection Algorithm for Digital CPT Stem in Total Hip Arthroplasty" a Industrial Computing Research Group, Universiti Kebangsaan Malaysia. , 11 (2013) 755 – 763.
9. Baker, 2011 R. P, A medium-term comparison of hybrid hip replacement and Birmingham hip resurfacing in active young patients.
10. Baleani M, *et al*, 2000, Endurance verification of custom made hip prosthesis, International

- Journal of Fatigue, 22, 865-871.
11. BeldameJ, 2009, Cementless cups do not increase osteolysis risk in metal-on-metal total hip arthroplasty, Orthopaedics and Traumatology Department, 95, 478—490.
 12. BergmannG, 2001, HIP98, Free University, Berlin, ISBN 3980784800 (Compact Disc).
 13. BergmannG, *et al*, 1993, Hip joint loading during walking and running, measured in two patients, Journal of Biomechanics, 26, 969-990.
 14. Bergmann G, *et al*, 1995, Influence of shoes and heel strike on the loading of the hip joint, Journal of Biomechanics, 28, 817-827
 15. BergmannG, *et al*, 1997, Hip joint forces during load carrying, Clinical Orthopaedics and related Research, 335, 190-201.
 16. BergmannG, *et al*, 2001, Hip contact forces and gait patterns from routine activities, Journal of Biomechanics, 34, 859-871.
 17. BertaniA, 2009, Total hip arthroplasty in severe segmental femoral bone loss situations: Use of a reconstruction modular stem design (JVC IXTM), Orthopedic Surgery Department, 95, 491—497.
 18. Biomaterials in total joint replacement, Colloids and surfaces B: Biointerfaces.
 19. Blake Latham and T.Goswami, 2004, Effect of geometric parameters in the design of hip implants paper IV, Materials and design, 25, 715-722.
 20. Brent M. Ardaugh, 2013, Be The 510(k) Ancestry of a Metal-on-Metal Hip Implant, The New England Journal of Medicine.
 21. BuffordA and T.Goswami, 2004, Review of wear mechanisms in hip implants : Paper I – General, Materials and design 25, 385-393.
 22. Catarina A. Oliveira, 2015, “A diagnosis not only in patients with metal-on-metal prostheses”, European Journal of Radiology Open 2 (2015) 3–6.
 23. Chang P. B, *et al*, 2001, Design and analysis of robust total joints replacements: Finite element model experiments with environmental variables, ASME Journal of Biomechanical Engineering, 123, 239-246.
 24. ChangP.B. *et al.*, 2001, Design and analysis of robust total joint replacements: Finite element model experiments with environmental variables, Journal of Biomechanical Engineering - ASME, 123, 239-246.
 25. Christopher N. Peck, 2011, Leg Length Discrepancy in Cementless Total Hip Arthroplasty, *Surgical Science*, 2, 183-187.
 26. Claire Brockett ,2007, Friction of Total Hip Replacements With Different Bearings and Loading Conditions, Journal of Biomedical Materials Research Part B: Applied Biomaterials. 508–515.
 27. Claire Brockett, 2006, “Friction of Total Hip Replacements With Different Bearings and Loading Conditions” Institute of Medical and Biological Engineering, School of Mechanical Engineering, University of Leeds, Leeds LS2 9JT, United Kingdom, 81B: 508–515.
 28. Claire L Brockett , 2008, The influence of clearance on friction, lubrication and squeaking in large diameter metal-on-metal hip replacements. Journal of Materials Science: Materials in Medicine, 19(4) 1575-1579.
 29. CliffordW.Colwell, 2010, Thrombosis Prevention After Total Hip Arthroplasty, The Journal of bone and joint surgery, J Bone Joint Surg Am. 2010;92:527-35.

30. CoganA, 2011, Occurrence of noise in alumina-on-alumina total hip arthroplasty. A survey on 284 consecutive hips, Department of Orthopaedics and Traumatology, 97, 206—210.
31. ColombiP, 2002, Fatigue analysis of cemented hip prosthesis: model definition and damage evolution algorithms, International Journal of Fatigue, 24, 895-901.
32. ColombiP., 2002, Fatigue analysis of cemented hip prosthesis: damage accumulation scenario and sensitivity analysis, International Journal Fatigue, 24, 739-746.
33. D’Lima D. D, *et al*, Standard for hip joint coordinate system, Recommendations from the ISB standardization committee.
34. Damien P. Byrne, 2010, Anatomy & Biomechanics of the Hip, Orthopaedic Research and Innovation Foundation, The Open Sports Medicine Journal, 2010, 4, 51-57.
35. DanielKelmanovich,2003, Surgical Approaches to Total Hip Arthroplasty, VOLUME 12, NUMBER 2.
36. DanSteinitz,2001, Ishomologous blood transfusion a risk factor for infection after hip replacement?, Canadian Journal of Surgery, Vol.44, No. 5
37. DayanandManjunath,2006, Early outcome of minimally invasive total hip arthroplasty, Transworld Medical Journal, 2(2):9093
38. Delaunay C, 2010, Metal-on-metal bearings total hip arthroplasty: The cobalt and chromium ions release concern, Department of Orthopaedic Surgery, 96, 894—904.
39. DI MonacoM, Systematic review of controlled trials on physical exercise programs European Journal of Physical and rehabilitation medicine, Vol. 45 - No. 3
40. DinkoVidovic, 2013, “Periprosthetic bone loss following hemiarthroplasty: a comparison between cemented and cementless hip prosthesis”, Department of Trauma and Orthopaedic Reconstructive Surgery, S3 S62–S66.
41. Eleftherios Tsiridis,2007, “Grafting for periprosthetic femoral fractures: Strut, impaction or femoral replacement,” Department of Trauma & Orthopaedics, 38, 688—697.
42. El-SheikhH. F, *et al*, 2003, Finite Element simulation of the hip joint during stumbling: a comparison between static and dynamic loading, Journal of Materials Processing Technology (Accepted for publication in 2003)
43. El-SheikhH. F,*et al*, 2002, Material selection in the Design of the Femoral component of cemented total hip replacement, Journal of Material Processing Technology, 122, 309-317.
44. Evans S. L, P.J. Gregson, 1998, Composite technology in loaded-bearing orthopedic implants, Biomaterials, 19, 1329-1342.
45. Fabiano BolpatoLoures, 2015, Cost-effectiveness of surgical treatment for hip fractures among the elderly in Brazil”, Orthopaedics & Traumatology: Surgery & Research (2010) 96, 44—48.
46. Fabiano BolpatoLouresa, 2015,” Cost-effectiveness of surgical treatment for hip fractures among the elderly in Brazil”, 50(1):38–42.
47. Fernando Judas, 2013, Treatment of Bilateral Recurrent Dislocation of Hip Prosthesis with Malpositioned Well-Fixed Shell: A Case Report, Journal of Orthopedics, , 3, 172-177.
48. GelalisI.D,2010 “Traumatic periprosthetic acetabular fracture treated by acute one-stage revision arthroplasty. A case report and review of the literature”, Department of Orthopaedic Surgery, 41 (2010) 421–424.

49. George Georgiou, 2006, "Dissociation of bipolar hemiarthroplasty of the hip after dislocation A report of five different cases and review of literature", Department of Orthopaedics, 37, 162—168.
50. George Grammatopoulos, 2011, A unique peri-prosthetic fracture pattern in well fixed femoral stems with polished, tapered, collarless design of total hip replacement, Nuffield Orthopaedic Centre, Oxford, United Kingdom, 42, 1271–1276.
51. Gianluca Mario Izzo, 2012, Structures modeling, Gait Data Analysis and Report system, European Journal Translational Myology - Basic Applied Myology ; 22 (1&2): 69-121.
52. Gomez-Benito M. *et al*, 2005, Finite element prediction of proximal femoral fracture patterns under different loads, Journal of Biomechanical Engineering, 127, 9-14.
53. Grimaldi, 2009, "Simultaneous bilateral femoral neck fractures secondary to epileptic seizures: Treatment by bilateral total hip arthroplasty", Orthopaedics & Traumatology: Surgery & Research (2009) 95, 555—557.
54. GX Ni, WW Lu, KY Chiu, 2005, Cemented or uncemented femoral component.
55. Hakan Cicek, 2015, "What should be the preferred choice of hemiarthroplasty technique in American Society of Anesthesiologists (ASA) class III patients with femoral neck fractures? Cemented or cementless", Orthopaedi and Traumatology Department, Adana, Turkey, 46 (2015) 1567–1570.
56. Hallab N. *et al.*, 2003, Differences in the fretting corrosion of metal-metal and ceramic-metal modular junctions of total hip replacements, Journal of orthopaedic research.
57. Hertzler *et al*, 2002, Fatigue crack growth rate does not depend on mantle thickness: an idealized cemented stem construct under torsional loading, Journal of orthopaedic research, 20, 676-682.
58. Hilal I. *et al*, 1999, Virtual Animation of the Kinematics of the Human for Industrial, Educational and Research Purposes, Information Societies Technology (IST) Programme. (<http://www.ulb.ac.be/project/vakhum/>).
59. Hindocha S, 2007, "Atraumatic fracture neck of femur in Marfan's syndrome", Department of Orthopaedics, 38, 343—345.
60. Hsin-Pai Lee, 2009, "Importance of serum albumin level in the preoperative tests conducted in elderly patients with hip fracture", Department of Orthopaedic Surgery, 40 - 756–759.
61. Huijskes R. *et al*, 1992, The relationship between stress shielding and bone resorption around total hip stems and the effects of flexible materials, Clinical Orthopedics, 274, 124-134.
62. Hurwitz D. E. *et al.*, 2003, A new parametric approach for modeling hip forces during gait, Journal of Biomechanics, 36, 113-119.
63. J. Xi *et al* (2003), Shape analysis and parameterized modeling of hip joint, Transactions of ASME, 3, 260-265.
64. Jagwant Singh, 2010, Effects of tranexamic acid on blood loss during total hip arthroplasty, Journal of Orthopaedic Surgery; 18(3):282-6.
65. Jaramaz B, Range of Motion After Total Hip Arthroplasty: Experimental Verification of the Analytical Simulator, IRI-9422734.
66. Jeffrey N. Katz, Failures of Total Hip Replacement: A Population-Based Perspective, Department of Orthopaedic Surgery and Division of Rheumatology.

67. JessicaWilliams,2012,Radiographic evaluation of hip replacements.
68. Joshi M.*Get al*, 2000, Survey of stress analyses of the femoral hip prosthesis, Applied mechanics review, 53, 1, 1-18.
69. JOSHUA J. JACOBS, 2011, Corrosion of Metal Orthopaedic Implants , The Journal of Bone and Joint Surgery, MA 02492-3157.
70. Justine M Naylor, “Severe other joint disease and obesity independently influence recovery after joint replacement surgery: an observational study”.
71. KaddickC, *et al*, 1997, Mechanical simulation of composite hip stems, Medical Engineering and Physics, 19(5), 431-439.
72. Kalpit K. Patel, 2006, “Mu”ller straight stem total hip arthroplasty for fractured neck of femur”, Department of Trauma and Orthopaedic Surgery, 37, 727—733.
73. Kalra S, 2006, “Intracapsular hip fractures in end-stage renal failure”, Department of Trauma & Orthopaedics, 37, 175—184.
74. Kapstad R.NH., 2007, “Changes in pain, stiffness and physical function in patients with osteoarthritis waiting for hip or knee joint replacement surgery”, OsteoArthritis and Cartilage (2007) 15, 837e843.
75. KatoozianH,*et al*, 2001, Material optimization of femoral component of total hip prosthesis using fiber reinforced polymeric composites, Medical Engineering and Physics, 23, 503-509.
76. Kevin Heaton, 2002,Surgical Release of Iliopsoas Tendon for Groin Pain After Total Hip Arthroplasty, The Journal of Arthroplasty Vol. 17 No. 6 779.
77. Kigera J W M1, Okello, 2011, Posterior Hip Dislocation with Ipsilateral Femoral Neck Fracture: A Case Report And Review Of Literature, Volume 7 • The Annals of African Surgery.
78. KirkwoodR.*Net al*, 1998,Radiographic and non-invasive determination of the hip joint center location: Effect on hip joint angles, NACOB 98.
79. KouyoumdjianP,2012, “Clinical evaluation of hip joint rotation range of motion in adults”, Orthopaedic surgery and traumatology department”, 98, 17—23.
80. KowalczykP, 2001, Design optimization of cementless femoral hip prosthesis using finite element analysis, ASME Journal of Biomechanical Engineering, 123, 396-402.
81. Lan-Feng Zhang,2014, “Bond strength analysis of the bone cement- stem interface of hip arthroplasties”. Asian Pacific Journal of Tropical Medicine, 153-159.
82. Leah C. Elson,2013, Are Morbidly Obese Patients Undergoing Total HipArthroplasty at an Increased Risk For Component Malpositioning?, The Journal of Arthroplasty 28 Suppl. 1 41–44.
83. LennonandA.BP.J.Prendergast, 2001, Evaluation of cement stresses in finite element analyses of cemented orthopaedic implants, Journal of biomechanical engineering, ASME, 123, 623-628.
84. LiC, *et al*, 2002, Progressive failure analysis of laminated composite femoral prostheses for total hip arthroplasty, Biomaterials, 23, 4249-4262.
85. Lincolshire and goole ,Information for Patients Six Weeks after Hip Replacement Surgery, Orthopaedic Unit, Physiotherapy & Occupational Therapy.
86. LIU Xian-zhe, 2008 “Clinical observation of particulate cancellous bone impaction grafting in combination with total hip arthroplasty for acetabular reconstruction”, 1(5):301-305.

87. LIU Xian-zhe, 2008 “Total hip arthroplasty for treatment of elderly patients with comminuted intertrochanteric fracture accompanied by femoral head necrosis”, 1(5):301-305.
88. Mamatakumaripadhy *et al*, 2005, Three dimensional analysis of contact and interfacial stresses in artificial hip joint, IPROM05.
89. Mary O’Sullivan, 2008, Nursing contributions to mobilizing older adults following total hip replacement in Ireland, Journal of Orthopaedic Nursing.
90. Mattei L, 2011, “Lubrication and wear modelling of artificial hip joints: A review”, Department of Mechanical, Nuclear and Production Engineering, Tribology International 44 (2011) 532–549.
91. Matthew Slonaker and T. Goswami, 2004, Review of wear mechanisms in hip implants: Paper II – ceramics IG004712, Materials and design 25, 395-405.
92. Mavcic Bet *et al.*, 2002, Mathematical estimation of stress distribution in normal and dysplastic human hips, Journal of Orthopaedic Research, 20, 1025-1030.
93. Mayer D.M and J.A. Tichy, 2003, 3-D model of a total hip replacement in vivo providing hydrodynamic pressure and film thickness for walking and bicycling, Journal of Biomechanical Engineering, 125, 777-784.
94. McCormack B.A. Oet *et al* (1998), A statistical analysis of microcrack accumulation in PMMA under fatigue loading: applications to orthopaedic implant fixation, International journal of Fatigue, 20, 581-593.
95. Miller Zet *et al.*, 2002, Trabecular bone adaptation with an orthotropic material model, Journal of Biomechanics, 35, 247-256.
96. Monika Michalíková, 2010, The Digital Pre-Operative Planning of Total Hip Arthroplasty, The Digital Pre-Operative Planning of Total Hip Arthroplasty, Vol. 7, No. 3
97. Morris R. P, *et al*, Evaluation of synthetic composite femur bones for use in hip prosthesis studies: A photo elastic study, The University of Texas Medical Branch.
98. Murphy I.G, 2007, “Intraabdominal migration of a dynamic hip screw”, Department of Orthopaedics, 39, 230—231.
99. Myo Minn, 2012, The lubrication of poly(ether ether ketone) by an aqueous solution of nattokinase
100. Nancy E. Lane, 2007, Osteoarthritis of the Hip, The new england journal of medicine, 357:1413-21.
101. Neil M. Orpen, 2009, “Internal fixation of trochanteric fractures of the hip after surface replacement”, 40 (2009) 32–35 .
102. Nikolaus P, 2007, “Fatigue failure in the cement mantle of a simplified acetabular replacement model”, International Journal of Fatigue, 29, 1245–1252.
103. Okrajni J, 2007, Validation of computer models of an artificial hip joint, International Scientific Journal, Volume 28, Issue 5.
104. Ole-Christian L. , 2013, Fractures of the greater trochanter following total hip replacement, Department of Orthopaedic Surgery, 23 (2) : 143 – 146.
105. Passuti N, 2009, “Friction couples in total hip replacement”, Orthopedic and Traumatic Surgery Department, 95S, S27—S34.

106. Paul T. Williams, 2013, Effects of Running and Walking on Osteoarthritis and Hip Replacement Risk Medicine & Science in sports & exercise, 0195-9131/13/4507-1292/0.
107. Pawlikowski .M, *et al*, Process of hip joint prosthesis design including bone remodeling phenomenon, Warsaw University of Technology, Poland.
108. Philipp Henle, 2007, “Femoral head injuries: Which treatment strategy can be recommended?”, Department of Orthopaedic Surgery, 38, 478—488.
109. Philipp Kobbe, “Less invasive stailisation system (LISS) for the treatment of periprosthetic femoral fractures:A 3-year follow-up” Department of Orthopaedic Trauma Surgery, 39, 472—479.
110. PhilippDamm, 2015, “Postoperative Changes in In Vivo Measured Friction in Total Hip Joint Prosthesis during Walking.”.
111. Phillips A, 2001, Finite element analysis of the acetabulum after impaction grafting, The university of Edinburgh.
112. PilotP, 2006, “ Is minimally invasive surgery less invasive in total hip replacement? A pilot study”. (2008) 39, 472—479.
113. Praveen Mereddy, 2008, Peri-prosthetic fracture neck of femur following metal-on-metal Birmingham hip resurfacing treated by internal fixation., 40 (2009) 65–67.
114. Prendergast. P.J, Review paper - Finite element models in tissue mechanics and orthopaedic implant design, Clinical Biomechanics, Vol.12, No.6, 343-366, 1997.
115. Pyburn E and T.Goswami, 2004, Finite element analysis of femoral components paper III- hip joints, Materials and design, 25, 705-713.
116. Ramachandran Prabhakara, 2013, “Volumetric modulated arc therapy for prostate cancer patients with hip prosthesis”, Malabar Cancer Center, Thalassery, Kerala, India - 1 8, 209–213.
117. Ramakrishna .S, *et al*, 2001, Biomedical applications of polymer-composite materials: a review, Composite Science and Technology, 61, 1189-1224.
118. RiouallonG, “Common femoral artery intimal injury following total hip replacement. A case report and literature review”, *Orthopaedics and Traumatology Department* **95**, 154—158.
119. Roy Chowdhury S.K *et al.*, 2004, Wear characteristic and biocompatibility of some polymer composite acetabular cups, *Wear* 256, 1026-1036.
120. RSM Ling FRCS, 2009, The Long Term Results Of The Orginal Exeter Polised Cemented Femoral Component, The Hip Unit – Princess Elizabeth Orthopaedic Centre, 24(4):511-7.
121. Saikko V and O.Calonius, 2002, Slide track analysis of the relative motion between femoral head and acetabular cup in walking and in hip simulators, *Journal of Biomechanics*, 35, 455-464.
122. SandeshReddyYaratapalli, 2014, Functional and radiological outcomes of total hip replacement in nontraumatic indications, *Int.J.Curr.Microbiol.App.Sci* 3(3): 153-158.
123. Santis R.D *et al.*, Continuous fibre reinforced polymers as connective tissue replacement, *Composites science and technology*, (Article in press-2004).
124. Sargeant A and T.Goswami, 2004, Hip implants: paper V. Physiological effects, *Materials and design* (Article in press).

125. SathyaGanapathi, 2013, Musculoskeletal Modeling of Hip Joint and Fracture Analysis for Surgical Planning Using FEA, Department of Bio-medical Engineering, Volume 9 (2013), Issue 2.
126. Scifert C. F., *et al*, 1999, Finite element analysis of a novel design approach to resisting total hip dislocation, *Clinical Biomechanics*, 14, 697-703.
127. Scotchford C.A. *et al.*, 2003, Use of novel carbon fibre composite material for the femoral stem component of a THR system: in vitro biological assessment, *Biomaterials*, 24, 4871-4879.
128. Selvaduray .G, 2002, Design Specification and Material Selection of Total Hip Implants, San Jose State University (<http://www.sjsu.edu/>).
129. Senapati S. K, S. Pal, 2002, UHMWPE-ALUMINA ceramic composite, an improved prosthesis material for an artificial cemented hip joint, *Trends in Biomater. Artificial Organs*, 16(1), 5-7.
130. Shapi'i A, 2011, "An Automated Size Recognition Technique For Acetabular Implant In Totak Hip Replacement", Department of Orthopaedic and Traumatology.
131. Sibella F *et al.*, 2003, Biomechanical analysis of sit-to-stand movement in normal and obese subjects, *Clinical Biomechanics*, 18, 745-750.
132. Siegele D *et al.*, Stress analyses of ceramic hip joint heads under different loading conditions, *Fraunhofer-Institut für Werkstoff-mechanik, W'hlstraße*.
133. Simoes J. A, *et al*, 2000, Design of controlled-stiffness composite proximal femoral prosthesis, *Composites Science and Technology*, 60, 559-567.
134. Simon S. Jameson, "Cemented versus cementless hemiarthroplasty for intracapsular neck of femur fracture—A comparison of 60,848 matched patients using national data" , *National Orthopaedic Research and Surgical Outcomes*, Newcastle, UK, 44 , 730–734.
135. Srinivasan S, *et al*, 1999, 3-D global/local analysis of composite hip prosthesis- a model for multiscale structural analysis, *Composite Structures*, 45, 163-170.
136. Srinivasan S, *et al*, 2000, Structural Response and relative strength of a laminated composite hip prosthesis: effects of functional activity, *Biomaterials*, 21, 1929-1940.
137. Stansfield B. W., *et al*, 2003, Direct Comparison of calculated hip joint contact forces with those measured instrumented implants. An evaluation of a three-dimensional mathematical model of the lower limb, *Journal of Biomechanics*, 36, 929-936.
138. Stansfield B.W and A.C.Nicol, 2002, Hip joint contact forces in normal subjects and subjects with total hip prostheses: walking and stair and ramp negotiation, *Clinical Biomechanics*, 17, 130-139.
139. Stuart Kerrigan, Analysis of Total Hip Replacements Using Active Ellipses, Division of Applied Computing, University of Dundee.
140. Subramanyam Naidu Maripuri, 2007, "Technique of obtaining internal rotation radiographs in fractured neck of femur", *Trauma and Orthopaedics*, 38, 471—473.
141. Susan C. Scholes, 2013, "Ceramic-On-Ceramic Joints: A Suitable Alternative Material Combination", *Advances in Biomaterials Science and Biomedical Applications*.
142. syedzameer, Fatigue Analysis of Artificial Hip Joints.
143. Teoh S.H, 2000, Fatigue of biomaterials, *International Journal of Fatigue*, 22 825–837.

144. Teoh S.H. *et al.*, 2002, Anelasto-plastic finite element model for polyethylene wear in total hip arthroplasty, *Journal of Biomechanics*, 35, 323-330.
145. ÞrósturPétursson,2012,Bone and muscle assessment in patients undergoing total hip arthroplasty using HU based analysis,European Journal Translational Myology - Basic Applied Myology 22 (3): 147-152.
146. Varanasi R and A.Rajadurai, 2001, Fracture and stress analysis of prosthetic hip joint using finite element method, NSRS-4.
147. Venkatachalam A.K. , Hip Replacement in Neglected Acetabular Fractures.
148. VesaSaikko, 2015, ” Analysis of UHMWPE wear particles produced in the simulation of hip and knee wear mechanisms with the Random POD system”, 30–34.
149. Vinod Pallapu, 2014, Wear-contact analysis of hip implant coated with functionally graded material, *International Journal of Multidisciplinary Research and Development* ; 1(7): 439-443.
150. VOGT L, 2004 , Muscle Activation Pattern of Hip Arthroplasty Patients in Walking, Johann Wolfgang Goethe-University,Institute for Sport Sciences, *Research in Sports Medicine* 12: 1–9.
151. VolodymyrPakhaliuk, 2015, “Improving the Finite Element Simulation of Wear of Total Hip Prosthesis' Spherical Joint with the Polymeric Component”. 100 ,539 – 548.
152. Waide V *et al.*, 2004, Modeling the fibrous tissue layer in cemented hip replacements: experimental and finite element methods, *Journal of Biomechanics*.
153. Weisse B *et al.*,2003, Improvement of the reliability of ceramic hip joint implants, *Journal of Biomechanics*, 36, 1633-1639.
154. Wen-Chuan Chen, 2014, “A cementless, proximally fixed anatomic femoral stem induces high micromotion with nontraumatic femoral avascular necrosis:A finite element study”, *Department of Orthopaedics*. 2, 149-156.
155. WIERZCHOLSKI K.Ch,2006, Friction forces for human hip joint lubrication at a naturally permeable cartilage, *Int. J. of Applied Mechanics and Engineering*, vol.11, No.3, pp.515-527.
156. WolfH, 2007, “Minimally invasive ilioinguinal approach to the acetabulum” 38, 1170—1176.
157. Zimmerman S *et al.*, 2002, Outcomes of surgical management of total hip replacement in patients aged 65 years and older: cemented versus cementless femoral components and lateral or anterolateral versus posterior anatomical approach, *Journal of Orthopaedic Research*, 20, 182-191.